

Relationship between the presence of intrauterine fluid and cervical bacteria in heavy draft mares before and after mating

Akiko CHIBA^{1,2}, Yukari UJIE¹ and Takahiro AOKI^{1-3*}

¹Department of Applied Veterinary Medicine, Obihiro University of Agriculture and Veterinary Medicine, Hokkaido 080-8555, Japan

²United Graduate School of Veterinary Sciences, Gifu University, Gifu 501-1193, Japan

³Research Center for Global Agromedicine, Obihiro University of Agriculture and Veterinary Medicine, Hokkaido 080-8555, Japan

While intrauterine fluid (IUF) is observed as mucous in healthy mares during estrus, the presence of IUF during diestrus is an indicator of endometritis. Mating induces endometrial inflammation in healthy mares, called mating-induced endometritis, that disappears within 1–2 days after mating. On the other hand, it is also known that IUF remaining beyond 12 hr after mating can cause persistent inflammation, bacterial growth, and decreased fertility. This study aimed to investigate the relationship between the presence of IUF and cervical bacteria before and after mating. Mares were classified into three groups based on the degree of IUF: Grade 1 (G1), neither IUF nor echogenic lines at the inner lining of the uterus; Grade 2 (G2), small amount of IUF (<0.5 cm in diameter) or an echogenic lines in the intrauterine cavity; and Grade 3 (G3), obvious IUF (≥0.5 cm in diameter). The positive culture rates of G1, G2, and G3 mares before mating were 15.8% (n=6/38), 25.9% (n=7/27), and 31.8% (n=14/44), respectively, and did not differ significantly between the groups. After mating, the positive culture rates of G1, G2, and G3 mares were 18.2% (n=2/11), 56.1% (n=23/41), and 72.3% (n=34/47), respectively. The positive culture rates were significantly higher in G2 (P<0.05) and G3 (P<0.01) mares compared with G1 mares. These results from after mating suggest that not only mares with obvious IUF but also those with a small amount of IUF (<0.5 cm in diameter) or echogenic lines in the intrauterine cavity are at risk of mating-induced endometritis.

Key words: cervical bacteriological examination, intrauterine fluid, mating-induced endometritis, ultrasonography

J. Equine Sci.
Vol. 30, No. 4
pp. 75–79, 2019

Mating induces endometrial inflammation in mares. This physiological reaction eliminates extra spermatozoa and microorganisms, which disappear within 1–2 days post-mating [7]. This endometrial inflammation develops into persistent mating-induced endometritis and infertility in some mares [16]. Intrauterine fluid (IUF) is fluid present in the endometrial cavity, and it is a good indicator of endometritis during the diestrus period [1].

It is also known that the presence of more than 2 cm (height) of uterine fluid during estrus is a predictor of susceptibility to post-mating endometritis [2], although IUF also is observed as mucous in healthy mares during estrus [13]. Semen, microorganisms, and foreign substances introduced into the uterus during mating are removed through phagocytosis by polymorphonuclear neutrophils (PMNs) that migrate into the uterine lumen in response to cytokines produced by endometrial inflammation [18]. In addition, prostaglandin F_{2α} produced in the endometrium after ovulation causes myometrial contractions that eliminate inflammatory products [15]. If the IUF is not removed within 12 hr after contamination, it can cause persistent inflammation, thus decreasing fertility [11, 14, 15]. In a previous study, the number of mares retaining IUF decreased by 12 hr after artificial insemination (P=0.07) [17]. The presence of IUF

Received: March 29, 2019

Accepted: August 22, 2019

*Corresponding author. e-mail: aokit@obihiro.ac.jp

©2019 Japanese Society of Equine Science

This is an open-access article distributed under the terms of the Creative Commons Attribution Non-Commercial No Derivatives (by-nc-nd) License. (CC-BY-NC-ND 4.0: <https://creativecommons.org/licenses/by-nc-nd/4.0/>)

4–8 hr post-mating indicates low uterine clearance ability [12], and mares retaining IUF 12 hr post-mating are considered to have persistent mating-induced endometritis [14]. In another study, mares were treated when the height of the IUF exceeded 0.5 cm [9]. However, we have no proof suggesting that lack of IUF reflected no infection or inflammation.

The cervix, acting as a gate between the uterus and vagina, remains open from early estrus until after ovulation under the influence of increasing estradiol and decreasing progesterone concentrations, allowing for the elimination of mucus, excess spermatozoa, and contaminants introduced by breeding [15]. While bacteriological examination of the uterus using non-guarded cervical swabs was conducted in the 1960s and 1970s, this method is no longer used for diagnosing endometritis because of the risk of contamination [8]. In general, samples for bacteriological examination to diagnose endometritis are taken from the endometrium. Swabbing the endometrium and uterine flush are common methods used to examine endometritis in equine practice [5]. Ultrasonography is known as a practical evaluation method for uterine clearance ability after mating [2]. It is the easiest tool for technicians in equine reproduction, but it does not provide enough information to judge uterine condition. If examination of the cervix could be useful for evaluation of uterine clearance ability, more accurate information could be provided when deciding if treatment is needed or not. However, the natural opening of the cervix during early estrus and under inflammatory conditions might make bacteriological examination of the cervix useful for evaluating uterine clearance ability. Contamination might be minimized if cervical swabs are guided using a disinfected vaginal speculum to avoid touching the vaginal wall. Several studies have reported a correlation between bacterial contamination of the genital tract and IUF, although one of these studies observed IUF after experimental inoculation of *Escherichia coli* into the uterus of mares to induce endometritis [4]. The relationship between IUF and bacteriological contamination of the genital tract of mares after mating has not been reported. If IUF were a valid indicator of bacterial contamination of the uterus, ultrasonography could be used to diagnose bacterial contamination. This study aimed to investigate the relationship between the presence of IUF and bacterial contamination of the cervix before and after mating.

Materials and Methods

The study retrospective cohort included 49 heavy draft mares (43 crossbreeds between Percheron, Belgian, and Breton heavy draft mares; 6 Percheron mares), 2 to 21 years old, bred by natural mating at three stud farms (Tokachi area, Hokkaido, Japan) between February 2016 and June

2017. Nineteen mares were bred in both 2016 and 2017. Mares were bred with 5 stallions (crossbreeds between Percheron, Belgian, and Breton heavy draft mares). This study excluded mares bred in foal heat, diagnosed with urovagina, treated with antibiotics, or treated by uterine lavage within a week before breeding. Transrectal ultrasonography (5.0 MHz transducer, Honda Electronics Co., Ltd., Toyohashi, Japan) was performed every 2–3 days to observe the genitals. Mares were bred when they had a large follicle (>4 cm in diameter) and showed behavioral signs of estrus, and ovulation was confirmed 12–48 hr after mating. Ovulation was confirmed by confirmation of the presence of a corpus hemorrhagicum or disappearance of the follicle with ultrasonography. Samples of cervical swabs were collected twice from each mare during each heat. One sample was collected when a large follicle (>4 cm in diameter) was confirmed by ultrasonography and behavioral signs of estrus were observed, such as winking of the vulva and urination during a teasing test. Mating was done within 24 hr after a large follicle was confirmed. Another sample was collected when ovulation was confirmed with ultrasonography, 12–48 hr after mating with the stallion. Mares were classified into three groups based on the amount of IUF and the presence of echogenic lines in the uterus when ultrasonography was performed at before and after mating, as follows: Grade 1 (G1), neither IUF nor echogenic lines at the inner lining of the uterus; Grade 2 (G2), a small amount of IUF (<0.5 cm in diameter) or echogenic lines in the intrauterine cavity [10]; and Grade 3 (G3), obvious IUF (≥ 0.5 cm in diameter) [9] (Fig. 1). The vulva was scrubbed with 0.05% benzalkonium chloride and sprayed with 10% povidone-iodine solution. After 30 sec, the vulva was wiped with a paper towel and then sprayed with 70% ethyl alcohol. A vaginal speculum (Vaginal speculums for mare, Fujihira Industry Co., Ltd., Tokyo, Japan) and uterocervical forceps (Uterocervical forceps, Fujihira Industry Co., Ltd.) were immersed in 0.05% benzalkonium chloride and wiped with a paper towel before use. The vaginal speculum was inserted into the vagina to confirm the location of the cervix. A non-guarded culture swab (BD BBL CultureSwab, Japan BD, Tokyo, Japan) was grasped with the uterocervical forceps and inserted into the cervix. The intracervical surface was swabbed without touching the vaginal wall. The swab was smeared with blood agar (Trypticase Soy Agar with 5% Sheep Blood, Japan BD), followed by incubation for 24–48 hr at 37°C. The culture was considered positive if >90% of the colonies growing on the blood agar were of one species (Obihiro Clinical Laboratory Inc., Obihiro, Japan). Mixed cultures (more than three species) or those with less than five colonies were considered negative. Data were analyzed using the χ^2 test. Significance was defined as a *P* value of <0.05, and a tendency was reported when the *P* value was

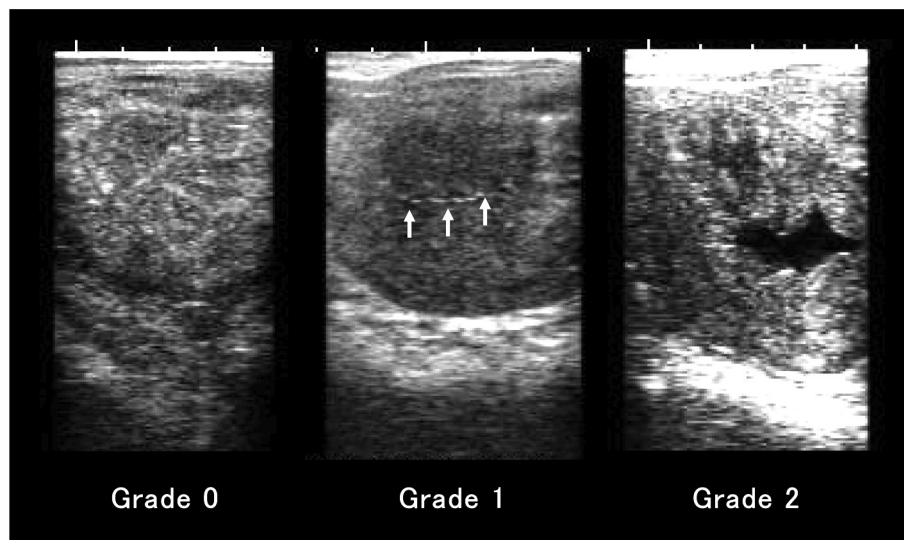


Fig. 1. Presence of intrauterine fluid as determined by transrectal ultrasound. Mares were classified into three groups based on the degree of intrauterine fluid (IUF) and the presence of echogenic lines in the uterus: Grade 0 (G0), neither IUF nor echogenic line at the inner lining of the uterus; Grade 1 (G1), a small amount of IUF (<0.5 cm in diameter) as an echo-free region or an echogenic line in the intrauterine cavity (arrows show an echogenic line); and Grade 2 (G2), obvious IUF (≥ 0.5 cm in diameter), with the scale of the echo-free region in this figure being 0.8×2.3 cm in diameter.

<0.1 but not <0.05. All statistical analyses were performed using Statcel4 (OMS Publishing Inc., Saitama, Japan).

Results

Mares were classified into three groups based on the degree of IUF and the presence of echogenic lines in the uterus. The numbers of G1, G2, and G3 mares were 38, 27, and 44 (total, 109), respectively, before mating, and they were 11, 41, and 47 (total, 99), respectively, after mating. The number of samples was larger than the number of mares ($n=46$) used in this study because some mares were bred more than once a year. Because mares treated after sampling before mating were excluded from the study, the numbers of samples before and after mating differ.

The positive culture rates of the G1, G2, and G3 mares before mating were 15.8% ($n=6/38$), 25.9% ($n=7/27$), and 31.8% ($n=14/44$), respectively, with no significant differences between the groups (Table 1). However, the number of G3 mares with positive cultures was about twice that of the G1 mares. After mating, the positive culture rates of the G1, G2, and G3 mares were 18.2% ($n=2/11$), 56.1% ($n=23/41$), and 72.3% ($n=34/47$), respectively. The positive culture rates for G2 ($P<0.05$) and G3 ($P<0.01$) mares were significantly higher than that of G1 mares. *Streptococcus zooepidemicus* was the most common isolate ($n=11$ before mating, $n=45$ after mating), followed by *Escherichia coli* ($n=6$ before mating, $n=7$ after mating). The relationship of

IUF grades between before and after mating is shown in Fig. 2. Compared with mares classified as G1 or G2 before mating, mares classified as G3 before mating tended to have a higher probability of being classified as G3 after mating ($P<0.1$).

Discussion

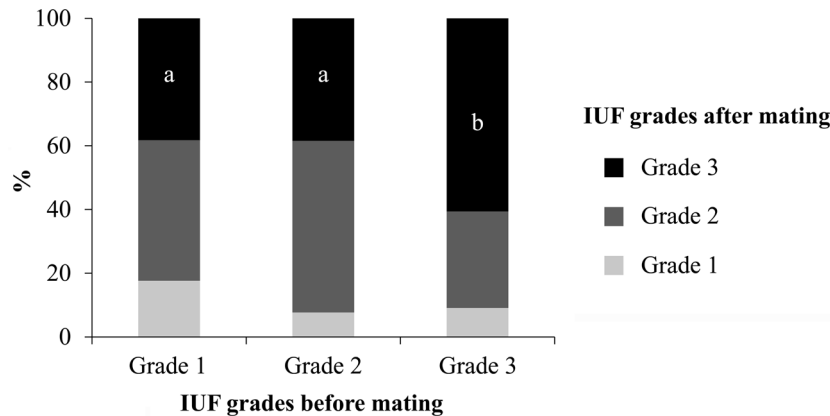
We observed that the positive cervical culture rates of mares increased with increasing volume of IUF after mating. Positive culture rates did not differ significantly according to the presence of IUF before mating. After mating, the positive culture rate differed significantly among G1, G2, and G3 mares. These results suggest that not only mares with obvious IUF but also those with a small amount of IUF (<5 mm in diameter) or echogenic lines in the intrauterine cavity are at risk of mating-induced endometritis.

No correlation was observed between the presence of IUF and cervical bacteria before mating. IUF can be present during estrus in the absence of endometrial infection or inflammation [9], likely reflecting the increased mucus secretion from the endometrium during this period. However, some of the mares in this study had positive bacterial cultures before mating. Possible reasons for the presence of bacteria before mating include persistent contamination from foaling or a previous mating and the introduction of bacteria from the normal genital flora [6] to the cervix through mucus. The possible reason for no

Table 1. Positive culture rates and the isolated microorganisms in cervical swabs collected from the mares in estrus at before and after natural mating by stallion

	Before mating			After mating		
	G1	G2	G3	G1	G2	G3
Positive culture rates (number)	15.8% (n=6/38)	25.9% (n=7/27)	31.8% (n=14/44)	18.2% ^{a, A} (n=2/11)	56.1% ^b (n=23/41)	72.3% ^B (n=34/47)
<i>Streptococcus zooepidemicus</i>	n=3	n=2	n=6	n=2	n=17	n=26
<i>Streptococcus sp.</i>					n=1	
<i>Escherichia coli</i>	n=1	n=2	n=3		n=2	n=5
<i>Corynebacterium renale</i>	n=1	n=1	n=1		n=1	
<i>Corynebacterium bovis</i>	n=1	n=1				
<i>Corynebacterium genitalium</i>					n=1	
<i>Corynebacterium sp.</i>						n=1
<i>Staphylococcus aureus</i>			n=1			
<i>Pseudomonas aeruginosa</i>			n=1			
<i>Klebsiella pneumoniae</i>			n=1			
<i>Staphylococcus schleiferi</i>			n=1			
<i>Enterobacter cloacae</i>		n=1				
<i>Enterobacter aerogenes</i>						n=1
<i>Kytococcus sedentarius</i>						n=1
<i>Bacillus circulans</i>					n=1	

Different letters indicate significant differences between the groups (a vs. b, $P < 0.05$; A vs. B, $P < 0.01$). G1, Grade 1; G2, Grade 2; G3, Grade 3.

**Fig. 2.** The relationship of intrauterine fluid (IUF) grades between before and after mating (a vs. b, $P < 0.1$).

correlation between IUF grade and detection of bacteria is that the mucus in estrus and effusion with bacterial infection or inflammation are not able to be distinguished by ultrasonography. The positive culture rate after mating was higher than that before mating because mating contaminated the vagina.

Our results indicate a correlation between the presence of IUF and bacterial contamination of the cervix after mating. After mating, the number of mares with positive cultures was significantly higher in those with G2 IUF than in those with G1 IUF. These results suggest that not only mares with obvious IUF but also those with a small amount of IUF (<5 mm in diameter) or echogenic lines in the intrauterine cavity

are at risk of mating-induced endometritis. In a previous study, β -hemolytic *Streptococcus* (37.8%), *Escherichia coli* (21%), *Staphylococcus aureus* (8.4%) were detected in the uterus of the mares with IUF [3]. In this study, β -hemolytic *Streptococcus* (52/78, 66.7%), *Escherichia coli* (12/78, 15.4%), *Staphylococcus aureus* (1/78, 1.3%) were detected in the cervix of G1 and G2 mares. The two most commonly detected species of bacteria were the same.

McKinnon *et al.* proposed that a small amount of IUF (<3 mm) does not require treatment [11]. We cannot make conclusions regarding the clinical significance of our observations because we did not investigate the relationship between fertility and the occurrence of endometritis after

mating in this study. However, it is suggested that even a small amount of IUF is related to infection or inflammation. IUF needs to be checked carefully, especially after mating, and treatment needs to be considered.

We assume that the time between ovulation and sample collection varied between mares. Thus, the endocrine changes and uterine contractions occurring in the mares might have differed. In a future study, the time between ovulation and sample collection should be considered when interpreting the results.

We found some relationships with respect to IUF grades between before and after mating. Compared with mares classified as G1 or G2 before mating, mares classified as G3 before mating tended to have a higher probability of being classified as G3 after mating. It is known that the presence of more than 2 cm (height) of uterine fluid during estrus is a predictor of susceptibility to post-mating endometritis [2]. The results of our study also suggest that mares with obvious IUF (≥ 0.5 cm in diameter) in the uterus before mating need a careful uterine examination after mating.

We observed a high positive culture rate among mares that had IUF remaining 12–48 hr after mating. In addition, those with an echogenic line in the uterine lumen also had higher positive culture rates after mating. We assume that one of the reasons for this result is that samples were obtained during the period in which contamination and sperm were eliminated from the uterus. There is a possibility that the cervix, the gate between the uterus and vagina, is a place where a microorganism can be detected even after it is eliminated from the uterus. Further studies of the relationships of these findings with mating-induced endometritis and fertility are needed to determine the clinical significance of our results.

References

- Adams, G.P., Kastelic, J.P., Bergfelt, D.R., and Ginther, O.J. 1987. Effect of uterine inflammation and ultrasonically-detected uterine pathology on fertility in the mare. *J. Reprod. Fertil. Suppl.* **35**: 445–454. [[Medline](#)]
- Brinsko, S.P., Rigby, S.L., Varner, D.D., and Blanchard, T.L. 2003. A practical method for recognizing mares susceptible to post-breeding endometritis. *Proc. Annual Convention of the Am. Assoc. Equine Pract.* **49**: 363–365.
- Burleson, M.D., LeBlanc, M.M., Riddle, W.T., and Hendericks, K.E.M. 2010. Endometrial microbial isolates are associated with different ultrasonographic and endometrial cytology findings in thoroughbred mares. *Proc. Annual Convention of the Am. Assoc. Equine Pract.* **56**: 317.
- Christoffersen, M., Woodward, E., Bojesen, A.M., Jacobsen, S., Petersen, M.R., Troedsson, M.H.T., and Lehn-Jensen, H. 2012. Inflammatory responses to induced infectious endometritis in mares resistant or susceptible to persistent endometritis. *BMC Vet. Res.* **8**: 41. [[Medline](#)]
- Diel de Amorim, M., Gartley, C.J., Foster, R.A., Hill, A., Scholtz, E.L., Hayes, A., and Chenier, T.S. 2016. Comparison of clinical signs, endometrial culture, endometrial cytology, uterine low-volume lavage, and uterine biopsy and combinations in the diagnosis of equine endometritis. *J. Equine Vet. Sci.* **44**: 54–61. [[CrossRef](#)]
- Hinrichs, K., Mummings, M.R., Sertich, P.L., and Kenney, R.M. 1990. Bacteria recovered from the reproductive tracts of normal mares. *Proc. Annual Convention of the Am. Assoc. Equine Pract.* **35**: 11–16.
- Katila, T. 1996. Uterine defence mechanisms in the mare. *Anim. Reprod. Sci.* **42**: 197–204. [[CrossRef](#)]
- Katila, T. 2016. Evaluation of diagnostic methods in equine endometritis. *Reprod. Biol.* **16**: 189–196. [[Medline](#)] [[CrossRef](#)]
- Knutti, B., Pycocock, J.F., Weijden, G.C., and K pfer, U. 2000. The influence of early postbreeding uterine lavage on pregnancy rate in mares with intrauterine fluid accumulations after breeding. *Equine Vet. Educ.* **12**: 267–270. [[CrossRef](#)]
- McCue, P.M., Scoggin, C.F., and Lindholm, A.R. 2011. Estrus. pp. 1716–1727. In: *Equine Reproduction*, 2nd ed. (McKinnon, A.O., Squires, E.L., Vaala, W.E., and Varner, D.D. eds.), Wiley-Blackwell, Ames.
- McKinnon, A.O., Squires, E.L., and Shideler, R.K. 1988. Diagnostic ultrasonography of the mare's reproductive tract. *J. Equine Vet. Sci.* **8**: 329–333. [[CrossRef](#)]
- Pycocock, J.F. 2006. How to maximize the chances of breeding successfully from the older maiden mare. *Proc. Annual Convention of the Am. Assoc. Equine Pract.* **52**: 245–249.
- Reilas, T., Katila, T., M kel , O., Huhtinen, M., and Koskinen, E. 1997. Intrauterine fluid accumulation in oestrous mares. *Acta Vet. Scand.* **38**: 69–78. [[Medline](#)]
- Troedsson, M.H.T. 1997. Therapeutic considerations for mating-induced endometritis. *Pferdeheilkunde* **13**: 516–520. [[CrossRef](#)]
- Troedsson, M.H.T. 1999. Uterine clearance and resistance to persistent endometritis in the mare. *Theriogenology* **52**: 461–471. [[Medline](#)] [[CrossRef](#)]
- Watson, E.D. 2000. Post-breeding endometritis in the mare. *Anim. Reprod. Sci.* **60–61**: 221–232. [[Medline](#)] [[CrossRef](#)]
- Watson, E.D., Barbacini, S., Berrocal, B., Sheerin, O., Marchi, V., Zavaglia, G., and Necchi, D. 2001. Effect of insemination time of frozen semen on incidence of uterine fluid in mares. *Theriogenology* **56**: 123–131. [[Medline](#)] [[CrossRef](#)]
- Woodward, E.M., Christoffersen, M., Campos, J., Betancourt, A., Horohov, D., Scoggin, K.E., Squires, E.L., and Troedsson, M.H. 2013. Endometrial inflammatory markers of the early immune response in mares susceptible or resistant to persistent breeding-induced endometritis. *Reproduction* **145**: 289–296. [[Medline](#)] [[CrossRef](#)]