

## Neuropathological Observation of Rabbits (*Oryctolagus cuniculus*) Affected with Raccoon Roundworm (*Baylisascaris procyonis*) Larva Migrans in Japan

Hidefumi FURUOKA<sup>1)</sup>, Hiroshi SATO<sup>2)</sup>, Midori KUBO<sup>1)</sup>, Shigeo OWAKI<sup>1)</sup>, Yoshiyasu KOBAYASHI<sup>1)</sup>, Takane MATSUI<sup>1)</sup> and Haruo KAMIYA<sup>2)</sup>

<sup>1)</sup>Department of Pathobiological Science, Obihiro University of Agriculture and Veterinary Medicine, Obihiro 080-8555 and

<sup>2)</sup>Department of Parasitology, Hirosaki University School of Medicine, Hirosaki 036-8562, Japan

(Received 15 August 2002/Accepted 17 February 2003)

**ABSTRACT.** Larvae of the raccoon roundworm, *Baylisascaris procyonis* (*B. procyonis*) are a known cause of cerebrospinal larva migrans in animals and humans. The present paper described details of the central nervous lesion in the rabbits (*Oryctolagus cuniculus*) affected with *B. procyonis* larva migrans in Japan. Clinically affected animals showed neurological signs including circling, torticollis, tremor of head, or ataxic gait. The most characteristic pathological alterations were large malacic lesions associated with an activated astroglial proliferation which was seen at the corpus medullare in the cerebellum including the cerebellar peduncle. Moreover, focal malacic lesions with perivascular cuffing and infiltration by lymphocytes and heterophiles were scattered everywhere throughout the brain. In these lesions or normal-appearing areas away from obvious lesions, ascarid larvae, about a maximum 65–75  $\mu\text{m}$  in diameter, were recognized. Other prominent features were minute lesions (we call them migration tract-like lesions) composed of lymphocytes, hemosiderin-laden macrophages and reactive astrocytes scattering throughout the cerebrum. In this study, we demonstrated ascarid larvae in only eight out of 23 animals diagnosed as *B. procyonis* larva migrans. Since it is not always possible to detect the larvae, the possibility of *B. procyonis* larva migrans must be given serious consideration to the characteristic lesions described above.

**KEY WORDS:** *Baylisascaris procyonis*, larva migrans, neuropathology, rabbit, raccoon.

*J. Vet. Med. Sci.* 65(6): 695–699, 2003

*Baylisascaris procyonis* (Nematoda, Family Ascarididae) is large roundworms common in raccoons (*Procyon lotor*), and has been emerged as an important cause of cerebrospinal nematodiasis in North America since the early 1980s [11]. Although this disorder had been the only recognized cause of avian cerebrospinal nematodiasis, it has become evident from spontaneous or experimental infection and a variety of species that *B. procyonis* is the most commonly recognized cause of clinical larva migrans in animals, having produced fatal or severe neurologic disease in over 90 species of birds and mammals, including humans [9].

According to a recent review [10], the parasite has been diagnosed or implicated as the cause of fatal or severe neurologic disease of 13 children [3,6,7,20,21], and was considered the cause of death in a child with an intracardiac eosinophilic mass [1]. *B. procyonis* is also a widely acknowledged cause of human ocular larva migrans, and frequently induces diffuse unilateral subacute neuroretinitis in North America and Europe [13, 14, 17].

Raccoons are indigenous to North America, but *B. procyonis* larva migrans has been reported in small animals kept in zoos in Germany [16] and Ireland [15], and a suspected case of German [17].

In the summer of 2000, we encountered an outbreak of *B. procyonis* larva migrans in rabbits [22]. We describe here the neuropathological findings in our cases. The CNS lesions in this disorder seemed to be stereotypical in rabbits [2, 4, 5, 8, 12, 19]. In this paper, we also note the newly recognized alterations, which we call migration tract-like lesions. These lesions seemed to be regarded as characteristic alterations in this disorder, however, a detailed descrip-

tion of these lesions were not given in the previous papers.

### MATERIALS AND METHODS

**Case histories:** From May to July 2000, among dozens of foxes, rabbits, and guinea pigs, and 12 raccoons in a small wildlife park in the eastern area of mainland Japan, approximately 10 rabbits showed neuroparalysis and died within about 10 days after the appearance of symptoms. In late July, five rabbits were pathologically diagnosed as cerebrospinal larva migrans due to *Baylisascaris* species in our laboratory. Clinically, these showed circling, torticollis, head tremors or ataxic gait, and cerebellar ataxia or vestibular dysfunction. After that, the infected cases increased in number, and two, four, ten and five were dissected in August, September, October and November, respectively. Although the exact ages of the affected animals were unknown, there was no apparent age or sex predilection. Parasitological and epidemiological studies, which have been reported in detail elsewhere [22], established the final identification of *B. procyonis*. Briefly, in this facility one young and two adult raccoons out of twelve were infected with *B. procyonis*, and an adult pet raccoon which was donated to this facility 8 weeks prior to the disease onset shed numerous eggs in its feces. By tissue digestion of two rabbits, seven heads of third-stage larvae of *B. procyonis* were recovered from the hindlimb and head/trunk muscles of a rabbit, but no larvae from the muscles of the other in whose cerebellum larvae were detected histopathologically.

**Animals:** Twenty-six rabbits (11 males, 12 females, and 3 of unknown cases) were submitted to our laboratory for

pathological examination from July to November 2000. Five had died after showing clinical signs, and the others were humanely destroyed.

**Histology and immunohistochemistry:** Samples collected from the central nervous system (CNS), including the trigeminal ganglia and spinal cord, along with the eyes and visceral organs, were fixed in 10% neutral buffered formalin, embedded in paraffin and sectioned at a 4  $\mu\text{m}$ -thickness. Sections were stained with H&E, PAS, Giemsa, Gram (MacCallum-Goodpasture method) and Gomori's trichrome. In addition, one hundred serial sections were made from some paraffin blocks of the CNS and carefully examined.

Immunohistochemistry was performed on selected sections of the CNS using the avidin-biotin-peroxidase complex (ABC) method with an ABC kit (Vector Lab., U.S.A.). The antibodies used in this study were monoclonal anti-rabbit macrophage (1:400, DAKO, U.S.A.) and monoclonal anti-human glial fibrillary acidic protein (GFAP)(1:2000, DAKO, Denmark). To assess the specificity of the immunostaining, normal mouse serum was substituted for the specific primary antibodies. Controls for all immunohistochemical reactions were negative.

## RESULTS

**Macroscopical findings:** Almost all cases were dehydrated and emaciated with scanty subcutaneous or abdominal fatty tissues. In some cases, multiple firm nodules were observed in the liver and lung. No abnormalities were seen in the CNS.

**Microscopic findings:** Lesions were observed in the CNS in 23 out of the 26 animals examined. These showed similar alterations with a similar distribution in the CNS (Fig. 1), although the severity and stage of the disease differed. The most characteristic features were large malacic lesions without hemorrhage seen at the corpus medullare in the cerebellum (including the cerebellar peduncle) (Fig. 2). In these lesions, perivascular cuffing and infiltration by lymphocytes and heterophiles were also observed. In the early stage, the lesions were characterized by numerous vacuolations of neuropils and accumulations of numerous foamy macrophages and gemistocytic astrocytes (Fig. 3). In some cases, abundant empty clefts formed by lipid crystals were also observed at the center of the malacic lesions (Fig. 4). At the more advanced stages, the lesions were replaced by severe fibrillary gliosis.

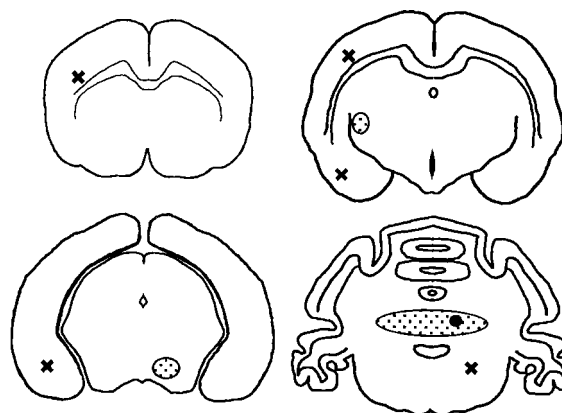


Fig. 1. Schematic pattern of the CNS lesions in the typical case. Solid circle=Larva; Dotted circles=Malacia; Cross marks=Migration tract-like lesions.

In some cross or a longitudinal sections, ascarid larvae which were about 65–75  $\mu\text{m}$  in diameter, were observed in above-mentioned lesions (Fig. 5). The cross sections showed the larval intestine located in the central portion, triangular excretory columns on each side of the intestine, and prominent, single, paired lateral alae. Larvae were found in both the cerebrum and cerebellum, with and without inflammatory reactions. Although these ascarid larvae were found in only eight of 26 animals examined, final diagnosis was based not only on observation of the larvae, but also on localization of the typical lesions mentioned above.

Focal lesions were scattered everywhere throughout the brain, but mainly in the cerebral cortex, midbrain, and brain stem; they were the same qualitative lesions as those seen in the cerebellum and were astroglia-associated malacic foci or focal necrosis. In the cerebellar cortex in some cases, focal cavitations or spongiosis were observed in association with necrosis, and calcific bodies in the granular layer and/or isomorphic gliosis in the molecular layer.

Other prominent features were minute lesions (we call them migration tract-like lesions), which were an accumulation of only a few cells associated with cleft-like spaces (Fig. 6). They were composed of lymphocytes, hemosiderin-laden macrophages and reactive astrocytes (Fig. 7) and were scattered throughout the cerebrum. Meningeal infiltrates and perivascular cuffing (including meningeal and

Fig. 2. Massive malacic lesion in the cerebellar medulla. Numerous vacuolations of neuropils and perivascular cuffing were present. H&E, Bar=0.5 mm.

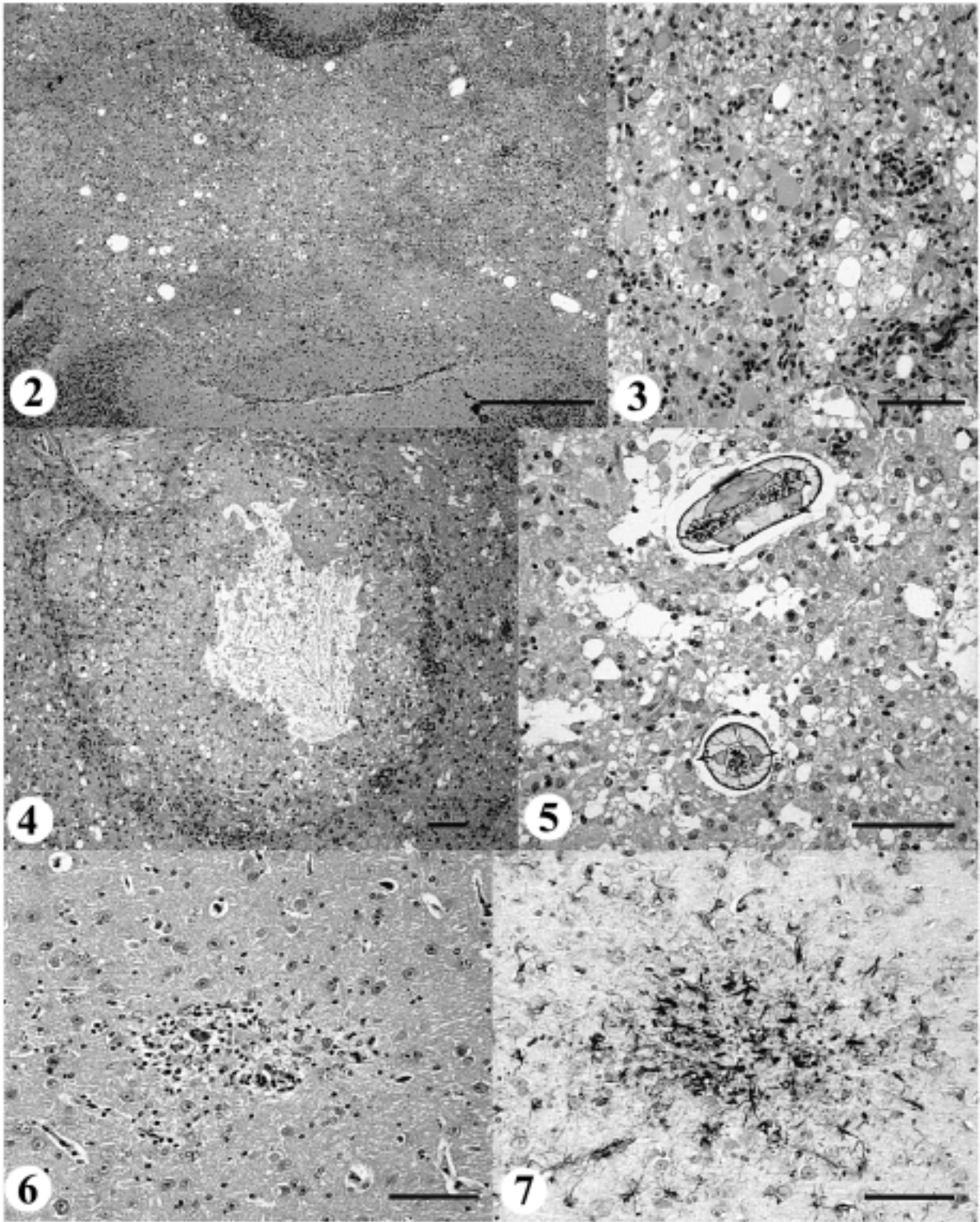
Fig. 3. Detail of Fig. 1 showing numerous gemistocytic astrocytes, foamy macrophages and lymphocyte infiltration. H&E, Bar=100  $\mu\text{m}$ .

Fig. 4. A cavity is formed in the center of a malacic lesion surrounded by fibrillary astrocytes and lymphocytes. Lipid crystals within macrophages are also observed. H&E, Bar=100  $\mu\text{m}$ .

Fig. 5. A cross section and longitudinally cut section of an ascarid larva is in a malacic lesion, identified as *B. procyonis*. H&E, Bar=100  $\mu\text{m}$ .

Fig. 6. Migration tract-like lesion in the cerebral cortex composed of lymphocytes and hemosiderin-laden macrophages. H&E, Bar=100  $\mu\text{m}$ .

Fig. 7. Serial section of Fig. 5. GFAP immunoreactive astrocytes are present around the lesion. ABC-peroxidase method with hematoxylin counterstain, Bar=100  $\mu\text{m}$ .



submeningeal vessels) of lymphocytes and heterophiles were also features of the inflammatory reaction in the brain.

No histological lesions were found in ocular sections. In several cases, granulomatous lesions caused by *Encephalitozoon cuniculi* infection were found in the CNS and kidney. In some cases, granulomatous lesions with calcification of the central area were seen in the liver and lung.

## DISCUSSION

The disease in the present rabbit cases was characterized by large malacic lesions at the corpus medullare of the cerebellum. In advanced cases, severe astrogliosis and/or cavitation were also observed. Although focal lesions of the migration tracts [10] were observed everywhere throughout the brain and spinal cord, the extensive lesions in the cerebellum appeared to be responsible for the clinical manifestations. Based on the distribution of histopathological lesions, the larvae seemed to reach and wander the cerebellum in the advanced stages of larva migrans. Such lesions seemed to be stereotypical in rabbits [2, 4, 5, 8, 12, 19] and other animals [10]. Localization of large malacic lesions even without the larvae are important for establishing the diagnosis.

Although the minute lesions (which we call migration tract-like lesions) were thought to be caused by larval migration, they did not appear to be the initial lesions nor to become infiltrated with additional inflammatory cells since astrogliosis reactions were observed. While the migration tract revealed as malacic foci showed a tendency to locate in the cerebellar cortex, midbrain, and brain stem, those minute lesions were observed mainly in the cerebrum. Since larvae passed quickly through the cerebrum, the lesions might escape the inflammatory reactions against larval excretory-secretory antigens and show vestiges of physical damage from larval migration.

Although in the present outbreak the number of rabbits available for parasitological examination was limited, seven larval heads were recovered from the muscles of an affected rabbit, but no larvae from another affected one [22], suggesting that only a few larvae may have produced the disease in the present cases. In this study, we demonstrated the ascarid larvae in only eight cases out of 23 animals diagnosed as *B. procyonis* larva migrans. Since it is not always possible to detect the larvae, a consideration to be *B. procyonis* larva migrans must be given to such lesions described above.

According to Miyashita [18], over 20,000 raccoons were imported into Japan as pets for 15 years starting in 1977. Now many naturalized raccoons inhabit in several areas of Honshu and Hokkaido, causing many ecological problems. *B. procyonis* has been found in both zoo-kept and pet raccoons in Japan. Fortunately, no cases of *B. procyonis* larva migrans had been reported in Japan, but its occurrence was predicted [18]. This outbreak poses a new public health problem in Japan, because *B. procyonis* causes one of the more severe zoonotic larva migrans due to its predilection for the CNS and its occurrence in animals foreshadows the

infection of humans as seen in North America [3,6,7,20,21] and Europe [17].

**ACKNOWLEDGEMENTS.** The authors thank Mr. Y. Saito and Ms. S. Murakami (staffs of the wildlife park) for their contributions to this work. This work was supported in part by a Grant-in-Aid for Scientific Research (B)(No. 13460137) from the Japan Society for the Promotion of Science.

## REFERENCES

1. Boshetti, A. and Kasznica, J. 1995. Visceral larva migrans induced eosinophilic cardiac pseudotumor: a cause of sudden death in a child. *J. Forensic. Sci.* **40**: 1097–1099.
2. Church, E. M., Wyand, D. S. and Lein, D. H. 1975. Experimentally induced cerebrospinal nematodiasis in rabbits (*Oryctolagus cuniculus*). *Am. J. Vet. Res.* **36**: 331–335.
3. Cunningham, C. K., Kazacos, K. R., McMillan, J. A., Lucas, J. A., McAuley, J. B., Wozniac, E. J. and Weiner, L. B. 1994. Diagnosis and management of *Baylisascaris procyonis* infection in an infant with nonfatal meningoencephalitis. *Clin. Infect. Dis.* **18**: 868–872.
4. Dade, A. W., Williams, J. F., Whitenack, D. L. and Williams, C. S. F. 1975. An epizootic of cerebral nematodiasis in rabbits due to *Ascaris columnaris*. *Lab. Anim. Sci.* **25**: 65–69.
5. Deeb, B. J. and DiGiacomo, R. F. 1994. Cerebral larva migrans caused by *Baylisascaris* sp. in pet rabbits. *J. Am. Vet. Med. Assoc.* **205**: 1744–1747.
6. Fox, A. S., Kazacos, K. R., Gould, N. S., Heydemann, P. T., Thomas, C. and Boyer, K. M. 1985. Fatal eosinophilic meningoencephalitis and visceral larva migrans caused by the raccoon ascarid *Baylisascaris procyonis*. *New Engl. J. Med.* **312**: 1619–1623.
7. Huff, D. S., Neafie, R. C., Binder, M. J., De Leon, G. A., Brown, L. W. and Kazacos, K. R. 1984. The first fatal *Baylisascaris* infection in humans: an infant with eosinophilic meningoencephalitis. *Pediatr. Pathol.* **2**: 345–352.
8. Jacobson, H. A., Scanlon, P. F., Nettles, V. F. and Davidson, W. R. 1976. Epizootiology of an outbreak of cerebrospinal nematodiasis in cottontail rabbits and woodchucks. *J. Wildl. Dis.* **12**: 357–360.
9. Kazacos, K. R. 1997. Visceral, ocular, and neural larva migrans. pp. 1459–1473. *In: Pathology of Infectious Disease*, vol. 2 (Connor, D. H., Chandler, F. W., Schwartz, D. A., Manz, H. J. and Lack, E. E. eds.), Appelton and Lange, Stamford, Connecticut.
10. Kazacos, K. R. 2001. *Baylisascaris procyonis* and related species. pp. 301–341. *In: Parasitic Diseases of Wild Mammals*, 2nd ed. (Samuel, W. M., Pybus, M. J. and Kocan, A. A. eds.), Iowa State University Press, Ames, Iowa.
11. Kazacos, K. R. and Boyce, W. M. 1989. *Baylisascaris* larva migrans. *J. Am. Vet. Med. Assoc.* **195**: 894–903.
12. Kazacos, K. R., Reed, W.M., Kazacos, E. A. and Thacker, H. L. 1983. Fatal cerebrospinal disease caused by *Baylisascaris procyonis* in domestic rabbits. *J. Am. Vet. Med. Assoc.* **183**: 967–971.
13. Kazacos, K. R., Vestre, W. A. and Kazacos, E. A. 1984. Raccoon ascarid larvae (*Baylisascaris procyonis*) as a cause of ocular larva migrans. *Invest. Ophthalmol. Vis. Sci.* **25**: 1177–1183.
14. Kazacos, K. R., Raymond, L. A., Kazacos, E. A. and Vestre ,

- W. A. 1985. The raccoon ascarid. A probable cause of human ocular larva migrans. *Ophthalmology* **92**: 1735–1744.
15. Kelly, W. R. and Innes, J. R. M. 1966. Cerebrospinal nematodiasis with focal encephalomalacia as a cause of paralysis of beaver (*Castor canadensis*) in the Dublin Zoological Gardens. *Br. Vet. J.* **122**: 285–287.
  16. Koch, F. and Rapp, J. 1981. Cerebral nematodiasis in nutria, attributed to infection with larvae of *Baylisascaris*. *Berl. Münch. Tierärztl. Wochenschr.* **94**: 111–114.
  17. Kühle, M., Knorr, H. L. J., Medenblik-Frysch, S., Weber, A., Bauer, C. and Naumann, G. O. H. 1993. Diffuse unilateral subacute neuroretinitis syndrome in a German most likely caused by the raccoon roundworm, *Baylisascaris procyonis*. *Graefes. Arch. Clin. Exp. Ophthalmol.* **231**: 48–51.
  18. Miyashita, M. 1993. Prevalence of *Baylisascaris procyonis* in raccoons in Japan and experimental infections of the worm to laboratory animals. *J. Urban Living Health Assoc.* **37**: 137–151 (in Japanese with English summary).
  19. Nettles, V. F., Davidson, W. R., Fisk, S. K. and Jacobson, H. A. 1975. An epizootic of cerebrospinal nematodiasis in cottontail rabbits. *J. Am. Vet. Med. Assoc.* **167**: 600–602.
  20. Park, S. Y., Glaser, C., Murray, W. J., Kazacos, K. R., Rowley, H. A., Fredrick, D. R. and Bass, N. 2000. Raccoon roundworm (*Baylisascaris procyonis*) encephalitis: case report and field investigation. *Pediatrics* **106**: E56.
  21. Rowley, H. A., Uht, R. M., Kazacos, K. R., Sakanari, J., Wheaton, W. V., Barkovich, A. J. and Bollen, A. W. 2000. Radiologic-pathologic findings in raccoon roundworm (*Baylisascaris procyonis*) encephalitis. *Am. J. Neuroradiol.* **21**: 415–420.
  22. Sato, H., Furuoka, H. and Kamiya H. 2002. First outbreak of *Baylisascaris procyonis* larva migrans in rabbits in Japan. *Parasitol. Int.* **51**: 105–108.