

Pathogenicity and diagnostic sensitivity of culture media for identification of *Trichomonas gallinae* in domestic pigeons of Lahore, Pakistan

Ali Raza ¹, Muhammad Fiaz Qamar ^{2*}, Nataliya Rubtsova ³, Syeda Saneela ⁴

¹ Department of Zoology, Government College University, Lahore 54000, Pakistan

² College of Veterinary & Animal Sciences, Jhang sub campus, University of Veterinary & Animal Sciences, Lahore 35200, Pakistan

³ Biology Department, Zaporizhzhya National University, Zhukovskoho Str., 66, 69000, Zaporizhzhya 69061, Ukraine.

⁴ Department of Zoology, University of Gujrat, Gujrat 50700, Pakistan.

*Corresponding author: Muhammad Fiaz QAMAR; E-mail: fiaz.qamar@uvas.edu.pk

ABSTRACT

Avian trichomoniasis is a serious infection caused by a trophozoite of *Trichomonas gallinae* (Rivolta, 1878) in domestic pigeons (*Columba livia domestica*). Different culture media are currently used for the *T. gallinae* identification in these hosts. Two commercially available cultured media, namely modified Diamond's medium and modified thioglycolate medium, were used to identify *T. gallinae* growth. Microscopic examinations of oral swabs of pigeons were carried out post inoculation by incubating at various temperature. Significant difference between incubation time found for modified Diamond's medium and Modified thioglycolate medium have been tested. Modified thioglycolate medium had been tested as a readily available, low-cost substitute for the Diamond's medium. Diamond's medium is considered as "gold standard" for identification *T. gallinae* in animals. However, modified thioglycolate medium was found to be practically efficient than Diamond's medium in recovering the parasites from specimens and may provide a readily available, low-cost substitute for the Diamond's medium. The current research also demonstrated the histopathology associated with infection of *T. gallinae*.

Keywords: modified Diamond's medium; modified thioglycolate medium; *Trichomonas gallinae*; histopathology

INTRODUCTION

Trichomonas gallinae causes massive losses in bird fauna due to high mortalities especially in columbiformes and is considered as one of most dangerous pathogens of pigeons in the world (Work and Hale, 1996; Villanua et al., 2006). There are very few investigations of this pathogen which affects domestic pigeons and its prevalence in them have been reported despite of its significance to the health of columbiformes all over the world, including Pakistan (McKeon et al., 1997; Dovc et al., 2004; Padilla et al., 2004; Luo et al., 2006; Sansano-Maestre et al., 2009; Zhang, 2009).

Trichomonas gallinae causes trichomoniasis in a variety of avian host orders. This protozoan occurs in various morphological forms such as round, stalked amoeboid, bell-shaped amoeboid and pyriform (Tasca and De Carli, 2003) and measures about 7–11 μm (Mehlhorn et al., 2009). It also has four anterior flagella and an axostyle. *T. gallinae* is not found in the cyst form (Levine, 1961). Kietzmann, (1993) showed that the bell-shaped amoeboid is potent to cause cell damage to avian palatal-esophageal epithelium during disease onset and progression. As the main host of *T. gallinae*, domestic pigeon plays an important role in the spread of this parasite among other members of the order causing morbidity and mortality.

Identification of *T. gallinae* can be done by making wet mount followed by Wright-Giemsa staining method and microscopic examination of oropharyngeal swab of infected birds (Kietzmann, 1993; Stabler, 1954; Coles, 1980; Anderson et al., 2009) or by the inoculation of such material culture on Diamond's medium (McKeon et al., 1997; Qiu et al., 2012; Kocan and Knisley, 1970; Amin et al., 2010), in Pouch TF kits by BioMed Diagnostics, California (Honigberg, 1978; Bunbury et al., 2005; Bunbury, 2011). Polymerase chain reaction (PCR) was also used to identify flagellated protozoan in wood pigeons (*Columba palumbus*) (Hofle et al., 2004).

The aims of current research were to check the histopathology of *T. gallinae* on tissues of domestic pigeons from Lahore (Pakistan) and to compare the sensitivity as well as efficiency of two different culturing media i.e. Modified Diamond's medium and Modified thioglycolate medium for proposing more efficient one for identifying *T. gallinae*.

MATERIALS AND METHODS

Grouping of Pigeons

Total 120 domestic pigeons were cage-reared in the animal house of Department of Zoology, Govt. College University Lahore, Pakistan. Pigeons were categorized according to their gender i.e. 78 males and 42 females. After measuring weight in grams using manual weight balance, pigeons were placed in four different categories of weight. The lowest range of weight was 181 grams and highest was 380 grams. Among those 14 pigeons were laying between 181-230 grams (A), 40 belonged to 231-280 (B), 38 belonged to 281-330 weight category (C), while 28 were in category of 331-380 (D).

Modified Diamond's medium

Oropharyngeal swabs were taken and inoculated to a modified Diamond's (Trypticase Yeast Maltose) medium. The culture medium was prepared including ingredients i.e. 20.0 g of trypticase, 10.0 g of yeast extract, 5.0 g of maltose, 1.0 g of L-cysteine hydrochloride, 0.2 g of ascorbic acid. Solution was brought up to 1,000 ml with distilled water; pH was maintained to 6.0 with 1N HCl and autoclaved for 15 min at 121°C under 15 lb/in² pressure to be sterilized. The 10 ml cultured medium was then dispensed in 12 ml screw cap vials. Each tube was then added 0.5 ml antibiotic mixture (Sodium penicillin G, Streptomycin sulfate, Grisiofulvin) and 1 ml inactivated fetal calf serum.

Sterile cotton swabs containing sample were inoculated in tubes containing modified Diamond's medium (Diamond, 1957; Kocan and Knisley, 1970; McKeon et al., 1997; Tasca and De Carli, 1999; Hofle et al., 2004; Qiu et al., 2012). Culture plates were observed up to 72 hour for presence of any live motile parasite using microscopy (Sansano-Maestre et al., 2009).

Modified thioglycolate medium

The commercially available fluid thioglycolate medium (HiMedia Laboratories, Mumbai, India) was purchased and dispensed in 10 ml screw cap vials/tubes. This medium was supplemented with 1 ml of sterile inactivated horse serum and 1 ml same antibiotic mixture prepared for modified Diamond's medium. Sterile cotton swabs were used to inoculate in modified thioglycolate medium. The presence of *T. gallinae* was diagnosed by taking 10 μ l of each culture daily from the bottoms of tubes and examined under binocular microscope studying characteristic morphology and motility of protozoa (Poch et al., 1996).

Incubation time

After the inoculation of swabs in modified Diamond's medium and modified thioglycolate medium, culture tubes were placed in the incubator 38 °C (\pm 0.5). Live protozoan growth was examined under microscope by taking 10 μ l of sample every 24 hours interval of post inoculation (PI) i.e. after 24 hours, 48 hours and 72 hours. Among both cultures which were diagnosed positive for *T. gallinae* were isolated from those which were remained negative until 72 hours. After the 72 hours, cultural vials were noted negative which showed no protozoan growth.

Histopathological preparation

For histopathology, we examined twenty severely infected pigeons after being found infected with *T. gallinae*. The complete postmortem examination of infected birds was performed and tissue specimens, of 0.5 cm thickness were collected from the pharynx, esophagus, crop, liver, and lungs to detect the different tissue reactions against the parasitic infections. The specimens were fixed in 10% neutral buffered formalin 48 to 72 hours and then washed with tap water. These specimens were dehydrated with ascending grades of alcohol, cleared with xylol. Five-micron thick paraffin sections were also prepared and stained with hematoxylin and eosin and examined microscopically.

Statistical analysis

The efficiency of two mentioned culturing media was compared by using Chi square test in SPSS for Windows (Release 16.0 standard version, SPSS Inc., Chicago, USA) (Villanua et al., 2006).

RESULTS

Incubation time

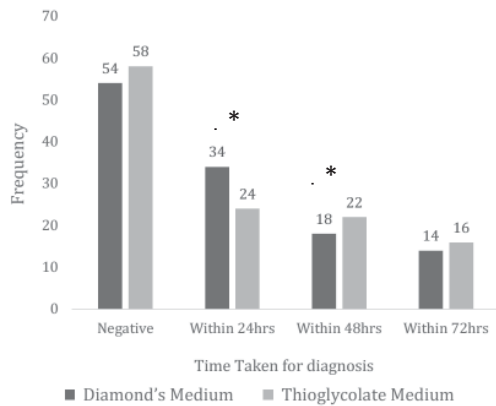
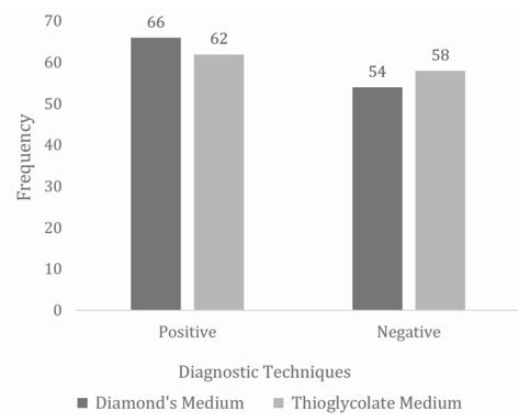


Fig. 1 showed different incubation times and the number of positive samples found on modified Diamond's medium and modified thioglycolate medium. We have found significant differences within 24 and 48 hours between incubation time for Modified Diamond's medium (CI 99%, $P < 0.001$) and for modified thioglycolate medium (CI 99%, $P < 0.001$).

Fig. 1. Incubation time taken by diagnostic methods for detection of *T. gallinae*. * Indicates $p < 0.001$ by Chi square test.

Comparison between diagnostic techniques



Both the modified Diamond's medium and the modified thioglycolate medium are found to be very sensitive for the detection of *T. gallinae*. Our data also suggest no significant difference at $P = 0.152$ between the number of positive samples diagnosed by modified Diamond's medium and modified thioglycolate medium (Fig. 2).

Fig. 2. The number of positive samples diagnosed by Diamond's and thioglycolate medium.

Modified Diamond's medium

We confirmed 66 (55%) samples positive for *T. gallinae* and 54 (45%) negative samples after final examination (Fig. 2). Among positive samples, 44 out of 66 were males. According to our results, among 42 female pigeons 22 were positive by modified Diamond's medium (Fig. 3). Sex related difference was not found among two groups for Diamond's medium as $P = 0.672$. The results showed much significant difference between weight groups

and number of positive samples diagnosed by the modified Diamond's medium ($P < 0.001$). Fig. 4 is showing the frequency of positive/negative samples by Diamond's medium among different weight groups.

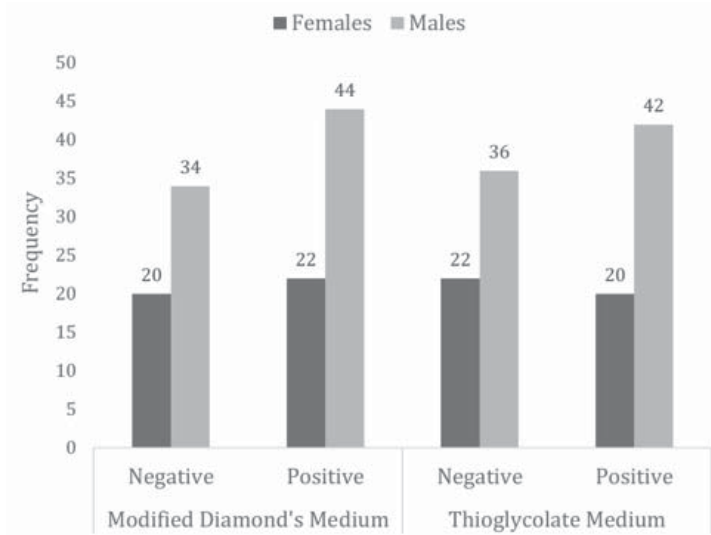


Fig. 3. The frequency of positive/negative samples by Diamond's medium and thioglycolate medium among two gender groups.

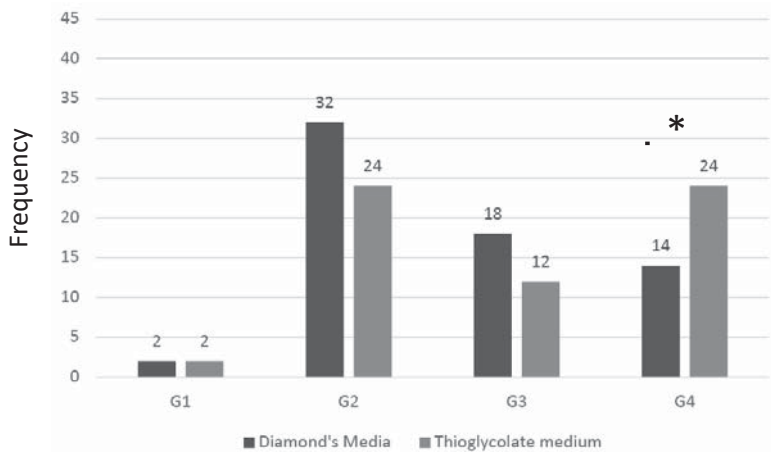


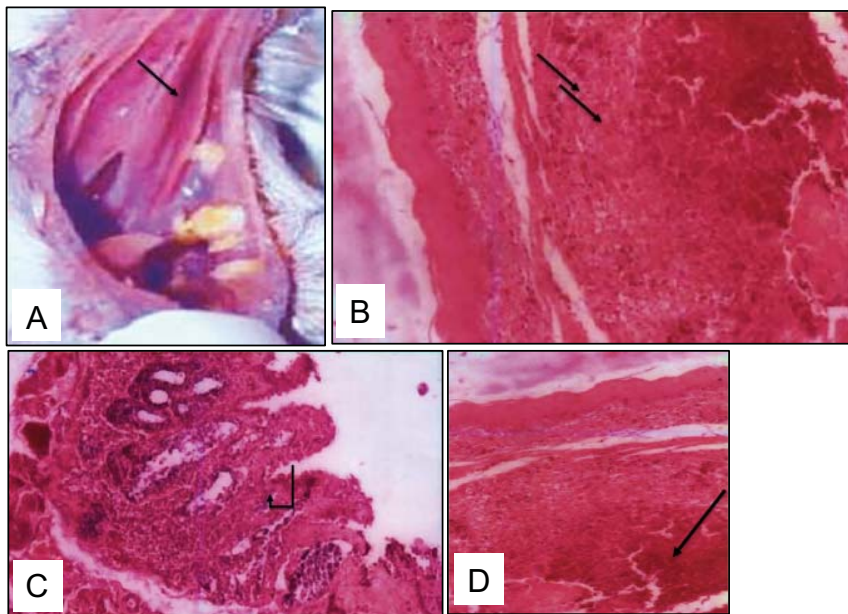
Fig. 4. The frequency of positive/negative samples by Diamond's medium and thioglycolate medium among different categories of weigh (grams). G1: 181-230 g, G2: 231-280 g, G3: 281-330 g, G4: 331-380 g. * Indicates $p < 0.001$ by Chi square test.

Modified thioglycolate medium

Our results have shown 62 (51.7%) of the samples of swabs taken, positive for *T. gallinae* and number of samples found to be negative is 58 (48.3%) (Fig. 2). According to our results, 20 samples were found to be positive female pigeons by thioglycolate medium. On the other hand, 42 males were positive in the diagnostic test (Fig. 3). We didn't find significant differences between gender groups for diagnosis by thioglycolate medium as $P = 0.515$. However, we found significant differences between weight groups for number of positive samples diagnosed by the thioglycolate medium ($P < 0.001$). Fig. 4 is showing the frequency of positive/negative samples by thioglycolate medium among different weight groups.

Histopathology

We examined five infected pigeons for histopathology from each group as macroscopically as well as histopathologically and the recorded lesions were persistent, all infected pigeons showed yellowish white caseated material varying in size in the pharyngeal mucosa, esophagus, and crop (Fig. 5A). Liver of pigeon naturally infected with *T. gallinae* showing an increase of necrosis in the hepatocytes (N = 10, Fig. 5B). Esophagus of pigeon squab naturally infected and not treated showing necrosis of the epithelial cells and leukocytic infiltration in the mucosa (N = 10, Fig. 5C). The histological sections of the crop of pigeons naturally infected with *T. gallinae* showed necrosis with inflammatory cells infiltration (N = 12, Fig. 5D). Massive infiltration was detected in the pharyngeal wall of the infected pigeons (N = 12, Fig. 5E). Lungs were severely congested with infiltration of mononuclear inflammatory cells and showed hemorrhage (N = 10, Fig. 5F).



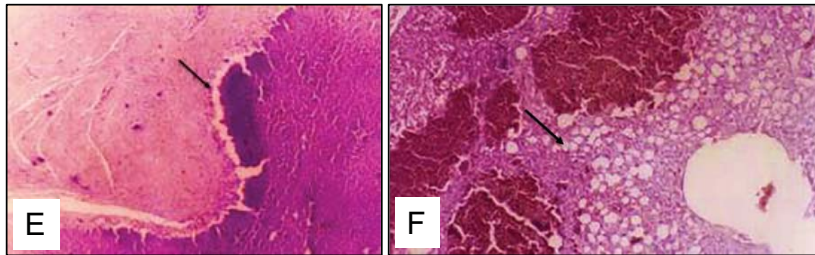


Fig. 5. (A) Yellow necrotic masses of variable size in the oral mucosa of a pigeon with trichomoniasis. (B) Liver of pigeon squab naturally infected with *T. gallinae* showing necrosis in the hepatocytes, H & E stain ($\times 200$). (C) Esophagus of pigeon squab naturally infected with *T. gallinae* showing necrosis of the epithelial cells and leukocytic infiltration in the mucosa, H & E stain ($\times 400$). (D) Crop of pigeon squab naturally infected with *T. gallinae* showing necrosis in the submucosa, H&E stain ($\times 400$). (E) Pharynx is showing massive necrosis of the pharyngeal wall, H & E stain ($\times 200$). (F) Trichomoniasis with lung showing congestion and hemorrhage, H & E stain ($\times 10$).

DISCUSSION

Cell culture media such as Diamond's TYM (Trypticase, Yeast extract, Maltose) (Diamond, 1957), fluid thioglycolate (Poch et al., 1996) and almost all media suitable for cultivation of other trichomonad will within pH limits the growth of *T. gallinae*. Diamond's medium which is having less or no ager content is at the advantage over other culture media. Shorb and Lund (1959) described that three components were necessary for growth in their synthetic assay medium for *T. gallinae*. These components included the factor R in unpurified ribonucleic acid, factor S in the bovine serum and the factor T in trypticase. According to Diamond (1986), the addition of serum has been considered an essential element for the growth of trichomonad strains in the culture because it is a rich source of amino acids, fatty acids and some trace elements. A recent study demonstrated greater quantities of freely moving flagellates obtained from cultures containing 10% fetal calf serum, which has a favorable effect on the growth of *T. gallinae* (Diamond, 1986).

Diamond (1954) has described method of cultivation for *T. gallinae* identification by using 28 different culture media. TYM (Trypticase, yeast extract, maltose) of the Diamond medium is considered as "a gold standard" for the cultivation of *T. gallinae*. A study which described comparison between cultures for diagnosis of *T. gallinae* infection in pigeons found Diamond's medium highly sensitive method for the identification of *T. gallinae* (Diamond, 1954). Recently Diamond's medium has become the most widely used culture medium used in the diagnosis of *T. gallinae* (Diamond, 1986).

Of the 120 birds examined in our study, we found 66 (55%) of the samples of swabs taken found to be positive for *T. gallinae* modified Diamond's medium (De Carli et al., 1979). Modified thioglycolate medium has shown 62 (51.7%) of the samples of swabs taken, positive for *T. gallinae*. Our data also suggests no significant difference in between modified Diamond's medium and modified thioglycolate medium (Poch et al., 1996).

The incubation time is a vital parameter that measures the efficiency of the methods used to identify protozoan growth. Furthermore, different incubation times and the number of positive samples by modified Diamond's medium and modified thioglycolate medium examined. We have found significant differences between incubation time for modified Diamond's medium and for modified thioglycolate medium. Regarding the efficiency of the both culture media, incubation time showed strong significant association between these techniques at $P < 0.05$ (Cover et al., 1994).

Although we have found more male positives as compared to females, we found no significant sex-related difference in diagnosis of *T. gallinae* between modified Diamond's medium and modified thioglycolate medium as $P > 0.05$ (Gulegen et al., 2005; Villanua et al., 2006). Our results show significant divergence from Al-Sadi and Hamodi (2011) who suggested males as more susceptible for *T. gallinae*.

Perez-Mesa et al., (1961) observed that on the second day of infection, *T. gallinae* formed a uniform layer on the squamous epithelial surface of the pharyngeal papillae without accompanying inflammation in the underlying connective tissue except near the gland opening and mild mononuclear reaction of the sub mucosa. On the third day, they noticed shallow ulcers in the pharynx, focal necrosis of the liver accompanied by mononuclear heterophiles. Boils were situated in all zones of the liver lobes and trichomonads were difficult to identify. In certain cases, the parasite moves towards several other organs like lungs, heart and brain resulting in necrotic lesions and is even lethal to host (Stabler, 1954). Different studies reported lesions in mouth, crop and esophagus, proventriculus and liver (Soulsby, 1982; Begum et al., 2008). The esophageal portion of is mostly affected (Hinshaw, 1965).

Regarding the weight of animals, we found 11%, 33%, 31% and 23% of pigeons in 181-230, 231-280, 41-55 and 331-380 in the respective categories of weight in grams. We have found statistically significant differences between weight (grams) of pigeons and Diamond's medium and thioglycolate medium at $P < 0.001$. Unfortunately, we were unable to find the relevant reason of pigeons' weight loss due to trichomoniasis.

Diamond's medium is considered as "gold standard" for identification *T. gallinae* in animals. However, modified thioglycolate medium was found to be practically efficient as Diamond's medium in recovering the parasite from specimens and may provide a readily available, low-cost substitute for the Diamond's medium. Both are sensitive as well as methods for the diagnosis of *T. gallinae* in avian fauna especially the fancy bird in the laboratory. The present study also suggests that pigeons commonly reared in Lahore Pakistan are very much susceptible to *T. gallinae* infection irrespective to sex of pigeons.

ACKNOWLEDGEMENTS

Authors are thankful Department of Zoology, Government College University Lahore, Pakistan for providing the necessary funding, animal rearing and laboratory facilities for conduction of research and experiments. We are also grateful to the ethical committee Government College University Lahore, Pakistan for allowing use to perform experiments on animals.

CONFLICT OF INTEREST

The authors declare that they have no conflict of interest.

SUBMISSION DECLARATION AND VERIFICATION

The authors declare that this manuscript is original, has not been published before and is not currently being considered for publication elsewhere.

REFERENCES

- Al-Sadi HI, Hamodi AZ. 2011. Prevalence and pathology of Trichomoniasis in free-living urban pigeons in the City of Mosul, Iraq Vet World. 4: 12-14.
- Amin A, Neubauer C, Liebhart D, Grabensteiner E, Hess M. 2010. Axenization and optimization of in-vitro growth of clonal cultures of *Tetratrichomonas gallinarum* and *Trichomonas gallinae*. Exp Parasitol. 124: 202-208.
- Anderson NL, Grahn RA, Van-Hoosear K, Bondurant RH. 2009. Studies of trichomonad protozoa in free ranging songbirds: Prevalence of *Trichomonas gallinae* in house finches (*Carpodacus mexicanus*) and corvids and a novel trichomonad in mockingbirds (*Mimus polyglottos*). Vet Parasitol. 61: 178-186.
- Begum N, Mamun MAA, Rahman SA, Bari ASM. 2008. Epidemiology and pathology of *Trichomonas gallinae* in the common pigeon (*Columba livia*). J Bangladesh Agril Univ. 6: 301-306.
- Bunbury N, Bell D, Jones C, Greenwood A, Hunter P. 2005. Comparison of the InPouch TF culture system and wet-mount microscopy for diagnosis of *Trichomonas gallinae* infections in the pink pigeon *Columba mayeri*. J Clin Microbiol. 43: 1005-1006.
- Bunbury N. 2011. Trichomonad Infection in Endemic and Introduced Columbids in the Seychelles. J Wildl Dis. 47: 730-733.
- Coles EH. 1980. Veterinary Clinical Pathology. Sounder's Company, Philadelphia.
- Cover AJ, Harmon WM, Thomas MW. 1994. A New Method for the Diagnosis of *Trichomonas gallinae*. Infection by Culture. J Wildl Dis. 30: 457-459.
- De Carli GA, Pansera MCG, Guerrero J. 1979. *Trichomonas gallinae* (Rivolta, 1878) Stabler, 1938, no trato digestivo superior de pombos domésticos, *Columba livia*, no Rio Grande do sul—primeiro registro. Acta Biol Leopoldensia, 1: 85-95 (article in Portuguese with an English abstract).
- Diamond L.S. 1957. The establishment of various *Trichomonas* of animals and man in axenic cultures. J Parasitol. 43: 488-490.
- Diamond LS. 1954. A comparative study of 28 culture media for *Trichomonas gallinae* Exp Parasitol. 3: 251-258.
- Diamond LS. 1986. In Vitro Cultivation of The Trichomonadidae: A State of The Art Review. Biologica 30: 221-22.
- Dovc A, Zorman-Rojs O, Vergles-Rataj A, Bole-Hribovsek V, Krapez U, Dobeic M. 2004. Health status of free-living pigeons (*Columba livia domestica*) in the city of Ljubljana. Acta Vet Hungarica. 52: 219-226.

- Gulegen E, Senlik B, Akyol V. 2005. Prevalence of trichomoniasis in pigeons in Bursa province, Turkey. *Indian Vet J.* 82: 369-370.
- Hinshaw WR. 1965. Diseases of the Turkey. pp. 1253-1263. In: Biester HF, Schwarte LH (eds), *Disease of poultry*, 5th edition, Iowa State University Press, Ames, Iowa.
- Hofle U, Gortazar C, Oritz JA, Knipsel B, Kaleta EF. 2004. Outbreak of trichomoniasis in a woodpigeon (*Columba palumbus*) wintering roost. *European Journal of Wildlife Research.* 50: 73 – 77.
- Honigberg BM. 1978. Trichomonads of importance in human medicine. In: Kreiger JP (ed), *Parasitic Protozoa*. Academic Press, Inc., New York.
- Kietzmann GE. 1993. Relationship of *Trichomonas gallinae* to the palatal–esophageal junction of ring doves (*Streptopelia risoria*) as revealed by scanning electron microscopy. *J Parasitol.* 79: 408-415.
- Kocan RM, Knisley JO. 1970. Challenge infection as a means of determining the rate of *Trichomonas gallinae*-free immune birds in a population. *J Wildl Dis.* 6: 13-15.
- Levine N.D. 1961. *Protozoan parasites of domestic animals and man*. Burgess publishing company, Minneapolis, Minnesota.
- Luo F, Weng YB, Zhang JF, Li GQ. 2006. A survey of *Trichomonas gallinae* in pigeons in Guangdong Province of China. *China Poultry.* 28: 24-25 (article in Chinese with an English abstract).
- Mckean T, Dunsmore J, Raidal SR. 1997. *Trichomonas gallinae* in budgerigars and columbid birds in Perth, Western Australia. *Australian Veterinary Journal.* 75: 652-655.
- Mehlhorn H, Al-Quraishy S, Aziza A, Hess M. 2009. Fine structure of the bird parasites *Trichomonas gallinae* and *Tetratrichomonas gallinarum* from cultures. *Parasitol Res.* 105: 751-756.
- Padilla LR, Santiago-Alarcon D, Merkel J, Miller RE, Parker PG. 2004. Survey for *Haemoproteus* spp., *Trichomonas gallinae*, *Chlamydophila psittaci*, and *Salmonella* spp. in Galapagos Islands columbiformes. *J Zoo Wildl Med.* 35: 60-64.
- Parker S, Campbell J, Gajadhar A. 2003. Comparison of the diagnostic sensitivity of a commercially available culture kit and a diagnostic culture test using Diamond's media for diagnosing *Tritrichomonas foetus* in bulls. *J Vet Diagn Invest.* 15: 460-465.
- Perez-Mesa CR, Stabler M, Berthrong M. 1961. Histopathological changes in the domestic pigeon infected with *Trichomonas gallinae* (Jones's Barn strain). *Avian Dis.* 5: 48-60.
- Poch F, Levin D, Levin S, Dan M. 1996. Modified thioglycolate medium: a simple and reliable means for detection of *Trichomonas vaginalis*. *J Clin Microbiol.* 34: 2630-2631.
- Qiu SB, Yan C, Zhou DH, Hou J, Wang QQ, Lin Y, Fu HC, Zhang J, Weng YB, Song HQ, Lin RQ. 2012. High prevalence of *Trichomonas gallinae* in domestic pigeons (*Columba liviadomestica*) in subtropical southern China. *African Journal of Microbiology Research.* 6: 3261-3264.

- Sansano-Maestre J, Garijo-Toledo MM, Gómez-Muñoz MT. 2009. Prevalence and genotyping of *Trichomonas gallinae* in pigeons and birds of prey. *Avian Pathol.* 38: 201-207.
- Shorb MS, Lund PG. 1959. Requirement of trichomonads for unidentified growth factors, saturated and unsaturated fatty acids. *J Parasitol.* 6: 122-130.
- Soulsby E JL. 1982. Helminths. pp. 562 -563. In: *Arthropods and Protozoa of Domesticated Animals*, 7th edition, Bailliere Tindall and Cassel Ltd. London.
- Stabler RM. 1954. *Trichomonas gallinae*: a review. *Exp Parasitol.* 3: 368-402
- Tasca T, De Carli GA. 2003. Scanning electron microscopy study of *Trichomonas gallinae*. *Vet Parasitol.* 118: 37-42.
- Tasca T, De Carli GA. 1999. Prevalence of *Trichomonas gallinae* from the upper digestive tract of the common pigeon, *Columba livia* in the Southern Brazilian State, Rio Grande Do Sul. *Parasitol Día.* 23, 42-43.
- Villanua D, Hofle U, Rodriguez LP, Gortazar C. 2006. *Trichomonas gallinae* in wintering common wood pigeons *Columba palumbus* in Ibis, Spain. *Intern J. Avian Sci.* 148, 641-648.
- Work TM, Hale J. 1996. Causes of owl mortality in Hawaii, 1992-1994. *J Wildl Dis.* 32: 266-273.
- Zhang XL. 2009. Prevalence of *Trichomonas gallinae* in pigeons in northern west of Shandong Province in China. *Chin J Vet Med.* 45: 56-57 (article in Chinese with an English abstract).