

Survey of *Sarcocystis* spp. Infection in Slaughtered Pigs in East Hokkaido, Japan

YOSHITAKA OMATA¹, A. OTTO HEYDORN², HANS-G. HEIDRICH³, IKUO IGARASHI⁴, ATSUSHI SAITO¹, HIDEO TOBA⁵ and NAOYOSHI SUZUKI⁴

¹Department of Veterinary Physiology, Obihiro University of Agriculture and Veterinary Medicine, Obihiro, Hokkaido, ²Institute for Parasitology and Tropical Veterinary medicine, Free University of Berlin, Berlin, Federal Republic of Germany, ³Max-Planck Institute for Biochemistry, Martinsried by Munich, Federal Republic of Germany, ⁴Research Center for Protozoan Molecular Immunology, Obihiro University of Agriculture and Veterinary Medicine, Obihiro, Hokkaido, Japan and ⁵Obihiro Meat Inspection Office, Obihiro, Japan

Received 25 December 1992 / Accepted 8 January 1993

Key words: pig, *Sarcocystis*, survey

Sarcocystis spp. being obligate heteroxenous coccidians, require definitive hosts in the course of their transmission. Prevalence of *Sarcocystis* infection in domestic animals have been reported in many countries (Barrows et al. 1981; Bottner et al. 1986; Munday 1975; Pereira and Bermejo 1988; Prestwood et al. 1980; Saleque and Bhatia 1991). Saito et al. (1986) documented the isolation of *Sarcocystis miescheriana* in 17 culled older pigs (17 / 200 = 8.5%) and none among fattened pigs in Saitama Prefecture, Honsyu, Japan. In the northern part of Japan, specifically in Hokkaido, to date, there are no published reports of *Sarcocystis* infection. Thus, the present study was sought to survey *Sarcocystis* infection among slaughtered pigs in East Hokkaido, Japan.

Samples of diaphragm muscle tissues were obtained from 104 sows, and 40 fattened pigs at a slaughter house in Obihiro, between October and November, 1992.

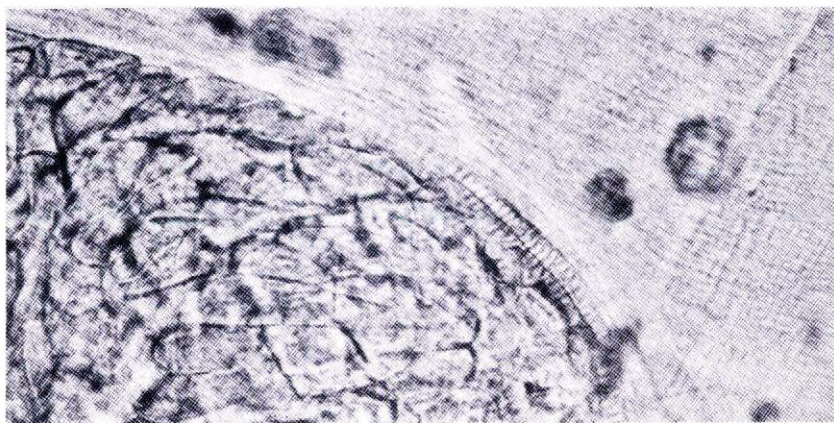


Figure 1. Cyst of *Sarcocystis suicanis* recovered from diaphragm of sow. Note perpendicular protrusions on the outer surface of cyst wall. x 400.

SARCOCYSTIS INFECTION IN EAST HOKKAIDO

Nine to fifteen pieces of muscle tissues, weighing approximately 0.5 g each, were excised from each host muscles and teased in phosphate buffered saline and examined microscopically. Identification of *Sarcocystis* spp. was based on morphological features, specifically on the structural dissimilarity of the cyst wall.

Cysts of *Sarcocystis suicanis* were detected in 17 out of 104 sows. Cysts were fusiform in shape and the cyst wall has radial, striated and perpendicular protrusions on the outer surface (Figure 1) containing numerous banana-shaped cystozoites. Among 40 fattened pigs, cysts of the more pathogenic and zoonotic *Sarcocystis suis hominis* which have cyst walls characterized as having hair-like villar and slanted protrusions on their outer surface were not found.

Results of the present study show a prevalence rate of 16.5 % of *S. suicanis* among sows and 0.0% occurrence of the pathogenic and zoonotic *S. suis hominis* in East Hokkaido. Non-utilization of human stool as manure for the past 10 years in Japan could be attributed as one major factor influencing the absence of contamination of soil with the zoonotic *S. suis hominis*. Furthermore, while this study does not provide information related to infection route of *S. suicanis* in sows in Hokkaido, the absence of wild pigs in the Hokkaido area, may lend support to the hypothesis that Honsyu areas would most likely be a source of *S. suicanis* in Hokkaido.

REFERENCES

- Barrows, P. L., Smith, H. M. Prestwood, A. K. & Brown, J. 1981. Prevalence and distribution of *Sarcocystis* sp among wild swine of southeastern United States. *JAVMA.*, 179:1117-1118.
- Bottner, A., Charleston, W. A. G., Pomroy, W. E. & Rommel, M. 1987. The prevalence and identity of *Sarcocystis* in beef cattle in New Zealand. *Vet. Parasitol.* 24: 157-168.
- Munday, B. L. 1975. The prevalence of sarcosporidiosis in Australian meat animals. *Austral. Vet. J.* 51: 478-480.
- Pereira, A. & Bermejo M. 1988. Prevalence of *Sarcocystis* cysts in pigs and sheep in Spain. *Vet. Parasitol.* 27: 353-355.
- Prestwood, A. K., Cahoon, R. W. & McDaniel, T. H. 1980. *Sarcocystis* infections in Georgia swine. *Am. J. Vet. Res.* 41: 1879- 1881.
- Saito, M., Nakajima, T., Watanabe, A. & Itagaki, H. 1986. *Sarcocystis miescheriana* infection and its frequency in pigs in Japan. *Jpn. J. Vet. Sci.* 48: 1083-1090.
- Saleque A. & Bhatia B. 1991. Prevalence of *Sarcocystis* in domestic pigs in India. *Vet. Parasitol.* 40: 151-153.