



# Classification of the seminiferous epithelial cycle in the sika deer (*Cervus nippon*)

著者 (英)	Hayakawa Daisuke, Sasaki Motoki, Suzuki Masatsugu, Igota Hiromasa, Kitamura Nobuo
journal or publication title	Mammal Study
volume	34
number	1
page range	41-45
year	2009
URL	<a href="http://id.nii.ac.jp/1588/00000649/">http://id.nii.ac.jp/1588/00000649/</a>

## **Classification of the Seminiferous Epithelial Cycle in the Sika Deer (*Cervus nippon*)**

Author(s): Daisuke Hayakawa, Motoki Sasaki, Masatsugu Suzuki, Hiromasa Igota and Nobuo Kitamura

Source: Mammal Study, 34(1):41-45.

Published By: Mammal Society of Japan

DOI: <http://dx.doi.org/10.3106/041.034.0107>

URL: <http://www.bioone.org/doi/full/10.3106/041.034.0107>

---

BioOne ([www.bioone.org](http://www.bioone.org)) is a nonprofit, online aggregation of core research in the biological, ecological, and environmental sciences. BioOne provides a sustainable online platform for over 170 journals and books published by nonprofit societies, associations, museums, institutions, and presses.

Your use of this PDF, the BioOne Web site, and all posted and associated content indicates your acceptance of BioOne's Terms of Use, available at [www.bioone.org/page/terms\\_of\\_use](http://www.bioone.org/page/terms_of_use).

Usage of BioOne content is strictly limited to personal, educational, and non-commercial use. Commercial inquiries or rights and permissions requests should be directed to the individual publisher as copyright holder.

## Classification of the seminiferous epithelial cycle in the sika deer (*Cervus nippon*)

Daisuke Hayakawa<sup>1,2</sup>, Motoki Sasaki<sup>1,2,\*</sup>, Masatsugu Suzuki<sup>3</sup>, Hiromasa Igota<sup>4</sup>  
and Nobuo Kitamura<sup>1,2</sup>

<sup>1</sup> Laboratory of Anatomy, Department of Basic Veterinary Medicine, Obihiro University of Agriculture and Veterinary Medicine, Obihiro 080-8555, Japan

<sup>2</sup> United Graduate School of Veterinary Medicine, Gifu University, Gifu 501-1193, Japan

<sup>3</sup> Laboratory of Zoo and Wildlife Medicine, Faculty of Applied Biological Science, Gifu University, Gifu 501-1193, Japan

<sup>4</sup> Department of Biosphere and Environmental Sciences, Rakuno Gakuen University, Ebetsu 069-8501, Japan

The sika deer (*Cervus nippon*) is the only Cervidae inhabiting Japan, except a feral foreign cervid, the Reeves' muntjac (*Muntiacus reevesi*). The sika deer is short-day seasonal breeder, and its rut occurs from October to December (Suzuki et al. 1992). When considering the biology of seasonal breeders, it is especially important to elucidate testicular functions during seasonal testicular changes. In the mature testes of the roe deer during the breeding season, the composition of the seminiferous epithelium periodically changes throughout spermatogenesis (Blottner et al. 1996). Many studies on the stages of the epithelial cycle have been reported in experimental and domestic animals (Foote et al. 1972; Swierstra et al. 1974; Berndtson 1977; Ekstedt et al. 1986; Pawar and Wrobel 1991). For example, the seminiferous epithelial cycle is divided into 14 stages in the rat (Leblond and Clermont 1952) and 8 stages in the bull (Wrobel and Schimmel 1989). Information about these stages is essential for morphological and functional researches on the testes and provides the basis of understanding testicular regulatory mechanisms (Toppari et al. 1986; Zhu et al. 1997; Zhou et al. 2002; Schön et al. 2004; Klonisch et al. 2006). In the rat, the morphological changes of the Sertoli cells with each seminiferous epithelial stage are concerned with the control of phosphorylation of the cytoskeletal protein, vimentin (Zhu et al. 1997). In the mouse, androgen receptors in the Sertoli cells show stage-dependent expression with the most intense expression in stages VI–VII (Zhou et al. 2002).

Histological studies on postnatal testicular development and seasonal changes of the testes have been reported in the sika deer (Yamauchi et al. 1982). Struc-

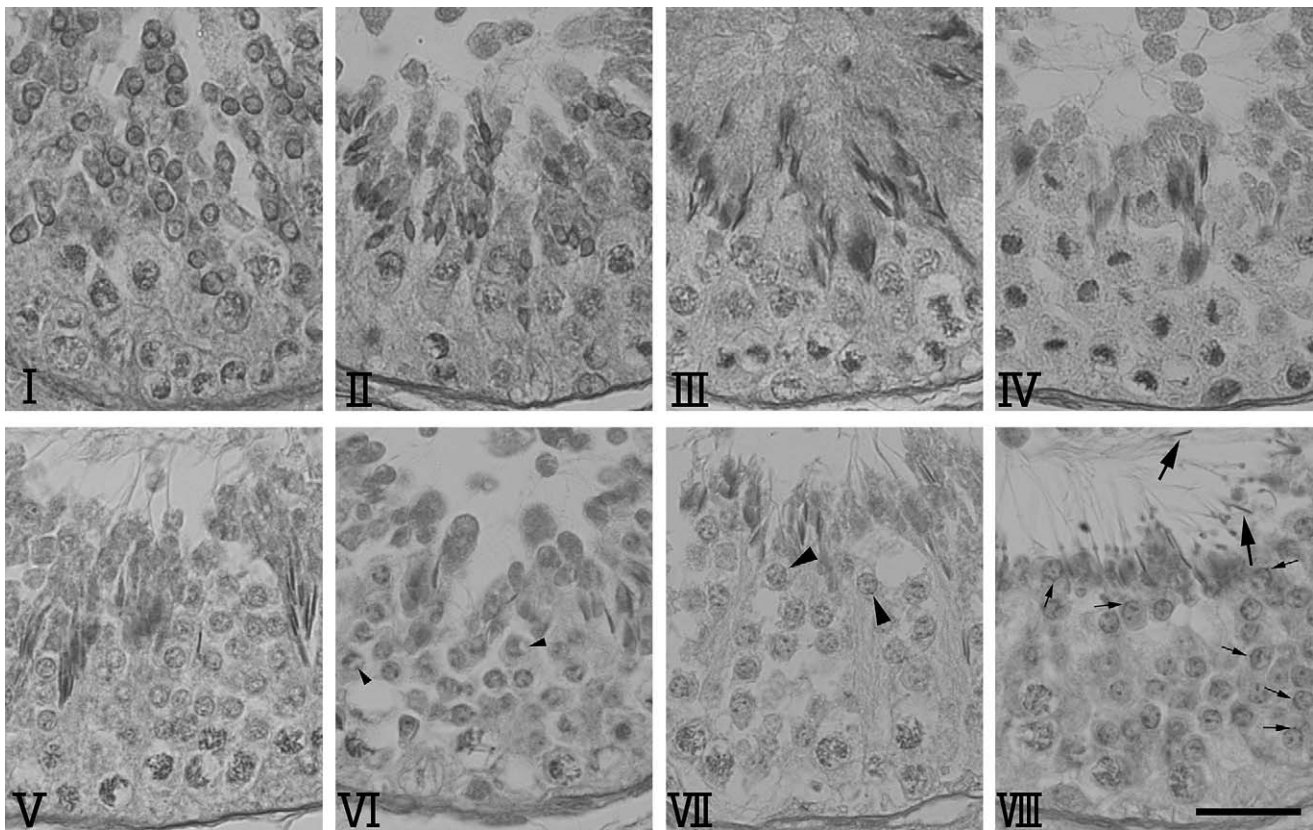
tural changes of the seminiferous tubules, plasma and fecal testosterone levels and localization of steroidogenic enzymes have already been examined with annual testicular changes of the sika deer (Suzuki et al. 1992; Yamauchi et al. 1997; Kameyama et al. 2002; Hayakawa et al. 2004). However, the stages of the seminiferous epithelial cycle are not yet fully defined in the sika deer, although they have been reported in other cervids, the fallow deer (Wrobel et al. 1993) and roe deer (Schön et al. 2004). In the present study, therefore, we categorized the seminiferous epithelial stages in the sika deer.

### Materials and methods

Testes were obtained from 10 adult male sika deer in Hokkaido, Japan (*Cervus nippon yesoensis*), in the autumn (October and November) of 2003. Samples from seven deer (more than 2-year-old) kept at a deer farm managed by the Town Office of Ashoro (Ashoro; 43°15'N, 143°33'E) were obtained in early October with official permission from Ashoro Town. Two wild deer (more than 2-year-old) were hunted in November in Nishiokoppe (44°20'N, 142°55'E) and one wild deer in Ohmu (44°35'N, 142°56'E). The age of each animal was estimated by assessing the branching of its antlers, as well as its dentition (Ohtaishi 1980).

Immediately following the death of each animal its testes were removed and fixed in Bouin's fluid. Fixed tissues were dehydrated in a graded series of ethanol, cleared in xylene, and embedded in paraffin (Paraplast Plus®, Kendall, MA., USA). The samples were then cut serially at 4 µm and placed on silane-coated glass slides. After deparaffinization, testicular tissue sections were

\*To whom correspondence should be addressed. E-mail: sasakim@obihiro.ac.jp



**Fig. 1.** Eight stages (I–VIII) of the seminiferous epithelium cycle of the sika deer. Small arrowheads: sphere acrosomal vesicle (in stage VI), large arrowheads: flattened acrosomal vesicle with an acrosome on the surface of the nuclear membrane (in stage VII), small arrows: more expanded acrosome (in stage VIII), large arrows: spermiation of spermatids (in stage VIII). PAS-hematoxylin staining. Bar = 25  $\mu$ m.

stained with hematoxylin and eosin (HE), and periodic acid Schiff (PAS)-hematoxylin. The seminiferous epithelial cycle was classified based on variations in the shape and localization of spermatogenic cells in round seminiferous tubules (Berndtson 1977). Moreover, the relative frequencies of each stage were estimated by counting round seminiferous tubules selected randomly because only one stage of the cycle was represented in one round tubule in the sika deer. More than 1000 tubules were counted in 10 individuals, according to a previous description (Wrobel et al. 1993).

## Results

The cellular formations of the seminiferous epithelium were classified as cycles based on meiotic division, variation in the shape of the spermatid, development of an acrosomal vesicle and release of spermatozoa into the lumen of the tubules (spermiation). The cycles of the seminiferous epithelium of the sika deer could be divided into 8 stages. In the sika deer testis, successive stages

were simultaneously found in one cross-sectioned tubule. The characteristics of each stage were as follows (Fig. 1).

Stage I: Characterized by no spermiation and cap phase spermatids with a flatly expanded acrosome on the surface of the nuclear membrane.

Stage II: The spermatids have entered the acrosome phase and started elongation.

Stage III: Acrosome phase spermatids continue their elongation, forming elongated spermatids.

Stage IV: Characterized by meiotic figures, and the secondary spermatocytes can be found only at this stage.

Stage V: Reveals two developmental processes of spermatids. Newly generated round spermatids (Golgi phase) contact the lateral aspects of the Sertoli cells. Former spermatids continue maturation. The pachytene of primary spermatocytes are found. In this stage, the acrosome is not present in the new spermatids.

Stage VI: Maturation phase spermatids are continuously shifted to a central position. A sphere acrosomal vesicle which connects with a nucleus is noticed in later

spermatids.

Stage VII: Maturation phase spermatids are continuously shifted to an apical position. Acrosomal vesicles change from sphere to flat and spermatids develop a flattened acrosome on the surface of the nuclear membrane.

Stage VIII: Characterized by spermiation (large arrows) and condensing residual bodies in the apical position. The acrosome expands the distributional area on the membrane and can be recognized more clearly.

On analysis of relative frequencies, the frequencies of stages of I, II, III, IV, V–VII and VIII were 12.9, 7.2, 23.8, 5.9, 22.9 and 27.3%, respectively. In the present study, stages V, VI and VII were grouped together as the maturation phase of spermatids.

## Discussion

In the present study, for the first time, the stages of the seminiferous epithelial cycle of the sika deer were examined, and 8 cycle stages were identified with only one stage of a seminiferous cross-section. Similar to the present results, most mammalian species have only one stage of the cycle in a cross-section of the seminiferous tubule (Johnson et al. 2000), although exceptions in which a section contains various stages of the spermatogenic cycle have been reported in the human (Clermont 1963) and marmoset (Millar et al. 2000; Li et al. 2005). This enables quantitative comparisons at relative frequency in the seminiferous epithelium cycle with many other mammals. In the present analysis of relative frequencies, stages V, VI and VII were grouped together as the maturation phase of spermatids, and this has already been applied in studies of the seminiferous epithelium of the bull (Wrobel and Schimmel 1989), water buffalo (Pawar and Wrobel 1991), fallow deer (Wrobel et al. 1993) and ram (Wrobel et al. 1995).

Stage I was defined by cap phase spermatids and no spermiation, stage IV by the meiotic division of spermatocytes, stage V by the occurrence of new round spermatids, and stage VIII by spermiation of spermatids. Moreover, stage VI and VII were distinguished by the development of acrosomal vesicle and the positioning of spermatids. In the sika deer, it was suggested that the process of spermatogenesis is not influenced by captive conditions with supplemental feeding and enclosure because no conspicuous differences were seen in seminiferous epithelial characteristics between wild and captive populations. The present results of the seminiferous epithelial cycle of the sika deer allow comparison with

those of many mammalian species, and could also be required to evaluate the testicular changes occurring under various conditions, such as aging, disease and exposure to endocrine disruptors.

The present findings indicate that the seminiferous epithelial cycle in the sika deer is similar to those in the vole and bank vole (Grocock and Clarke 1976), dog (Foote et al. 1972), blue fox (Andersen et al. 1990), maned wolf (Bitencourt et al. 2007), bear (Komatsu et al. 1996), cat (França et al. 2002), puma (Leite et al. 2006), horse (Swierstra et al. 1974), donkey and mule (Neves et al. 2002), grey squirrel (Tait and Johnson 1982), capybara (Paula et al. 1999), boar (Swierstra 1968; Almeida et al. 2006), bull (Wrobel and Schimmel 1989), water buffalo (Pawar and Wrobel 1991), ram (Wrobel et al. 1995), fallow deer (Wrobel et al. 1993) and roe deer (Schön et al. 2004) in that the cycle has 8 stages with a regular order of successive stages. However, it is different from the 14 stages in the rat (Leblond and Clermont 1952), Watase's shrew (Adachi et al. 1992) and greater Japanese shrew mole (Mizukami et al. 2001), the 12 stages in the tree shrew (Maeda et al. 1996), rhesus monkey (de Rooij et al. 1986), cynomolgus monkey (Dreef et al. 2007), mouse (Oakberg 1956), guinea pig (Noller et al. 1977), Djungarian hamster (van Haaster and de Rooij 1993) and Mongolian gerbil (Segatelli et al. 2004), the 10 stages in the Japanese macaque (Enomoto et al. 1994), and the 6 stages in the human (Clermont 1963). In the light of these previous studies, it is thought that ungulates and carnivores tend to have an 8-stage seminiferous epithelial cycle. On the other hand, the cycle of Soricomorpha is divided into 14 stages. Rodents have an epithelial cycle from 8 up to 14 stages. Primates also have different stage numbers of the seminiferous epithelial cycle among species. Although the cycle of the marmoset has 8 stages, like ungulates and carnivores, a cross section has multi-stages of the seminiferous epithelial cycle (Millar et al. 2000; Li et al. 2005; Dreef et al. 2007). It is not evident whether the number and continuation of stages are correlated with testicular functions, but the accumulation of functional morphological data of testes might classify the reciprocal relationships.

In the sika deer, the relative frequency of the 8-stage seminiferous epithelium cycle showed a low proportion in meiotic division (stage IV), similar to other ruminants; the fallow deer (Wrobel et al. 1993), roe deer (Schön et al. 2004), ram (Wrobel et al. 1995), and water buffalo (Pawar and Wrobel 1991). Thus, it is suggested that the period of time for meiotic division is short in a cycle of

the seminiferous epithelium of these ruminants.

Studies of general spermatogenic functions have been mainly performed using the testes of annual breeders. Thus, spermatogenic studies of seasonal breeders are important to elucidate the mechanisms of seasonal testicular involution and recrudescence. Suzuki et al. (1992) previously reported seasonal changes of the sika deer testes and indicated that the testes began to regress from December and were restored in July or August. In further studies, it will be important to examine which stage of the testicular epithelial cycle or which process of spermatogenesis is influenced by seasonal transition. The present data are noteworthy to consider seasonal changes in mammalian spermatogenesis and could be useful for subsequent studies on the testicular functions and morphology of the sika deer.

**Acknowledgments:** The present study was supported by a Grant-in-Aid for Scientific Research (The 21st Century Center-of-Excellence Program) from the Ministry of Education, Culture, Sports, Science and Technology of Japan (E-1). The authors would like to thank the Nishiokoppe Wildlife Association, Deer Farming Group and the Village Office of Nishiokoppe, the Yezo Deer Association, the Hunter's Association of Hokkaido, the Town Office of Ashoro and the members of the Deer Sampling Team of Hokkaido University for kind support with sampling. We wish to thank Dr. Tetsuro Koizumi (Tsuruminedouri Vet. Hosp.) for his useful information.

## References

- Adachi, Y., Kurohmaru, M., Hattori, S. and Hayashi, Y. 1992. Spermatogenesis in the Watase's shrew, *Crocidura watasei*—A light electron microscopic study—. *Experimental Animals* 41: 295–303.
- Almeida, F. F., Leal, M. C. and França, L. R. 2006. Testis morphometry, duration of spermatogenesis, and spermatogenic efficiency in the wild boar (*Sus scrofa scrofa*). *Biology of Reproduction* 75: 792–799.
- Andersen Berg, K., Clausen, O. P. and Huitfeldt, H. S. 1990. The spermatogenic cycle in the blue fox (*Alopex lagopus*): relative frequency and absolute duration of the different stages. *International Journal of Andrology* 13: 315–326.
- Berndtson, W. E. 1977. Methods for quantifying mammalian spermatogenesis: a review. *Journal of Animal Science* 44: 818–833.
- Blottner, S., Hingst, O. and Meyer, H. H. D. 1996. Seasonal spermatogenesis and testosterone production in roe deer (*Capreolus capreolus*). *Journal of Reproduction and Fertility* 108: 299–305.
- Bitencourt, V. L., de Paula, T. A., da Matta, S. L., Fonseca, C. C., dos Anjos Benjamin, L. and Costa, D. S. 2007. The seminiferous epithelium cycle and daily spermatic production in the adult maned wolf (*Chrysocyon brachyurus*, Illiger, 1811). *Micron* 38: 584–589.
- Clermont, Y. 1963. The cycle of the seminiferous epithelium in man. *American Journal of Anatomy* 112: 35–45.
- de Rooij, D. G., van Alphen, M. M. and van de Kant, H. J. 1986. Duration of the cycle of the seminiferous epithelium and its stages in the rhesus monkey (*Macaca mulatta*). *Biology of Reproduction* 35: 587–591.
- Dreef, H. C., Van Esch, E. and De Rijk, E. P. 2007. Spermatogenesis in the cynomolgus monkey (*Macaca fascicularis*): a practical guide for routine morphological staging. *Toxicologic Pathology* 35: 395–404.
- Ekstedt, E., Söderquist, L. and Plöen, L. 1986. Fine structure of spermatogenesis and Sertoli cells (Epithelicytus sustentans) in the bull. *Anatomia Histologia Embryologia* 15: 23–48.
- Enomoto, T., Matsubayashi, K., Nagato, Y. and Nakano, M. 1994. Seasonal changes in the spermatogenic epithelium of adult Japanese macaques (*Macaca fuscata fuscata*). *Primates* 35: 465–472.
- Foote, R. H., Swierstra, E. E. and Hunt, W. L. 1972. Spermatogenesis in the dog. *The Anatomical Record* 173: 341–350.
- França, L. R. and Godinho, C. L. 2002. Testis morphometry, seminiferous epithelium cycle length, and daily sperm production in domestic cats (*Felis catus*). *Biology of Reproduction* 68: 1554–1561.
- Grocock, C. A. and Clarke, J. R. 1976. Duration of spermatogenesis in the vole (*Microtus agrestis*) and bank vole (*Clethrionomys glareolus*). *Journal of Reproduction and Fertility* 47: 133–135.
- Hayakawa, D., Sasaki, M., Akabane, C., Kitamura, N., Tsubota, T., Suzuki, M. and Yamada, J. 2004. Immunohistochemical localization of steroidogenic enzymes in the testis of Hokkaido Sika deer (*Cervus nippon yesoensis*). *Journal of Veterinary Medical Science* 66: 1463–1466.
- Johnson, L., Varner, D. D., Roberts, M. E., Smith, T. L., Keillor, G. E. and Scrutchfield, W. L. 2000. Efficiency of spermatogenesis: a comparative approach. *Animal Reproduction Science* 60–61: 471–480.
- Kameyama, Y., Miyamoto, A., Kobayashi, S., Kuwayama, T. and Ishijima, Y. 2002. Annual changes in serum LH and testosterone concentrations in male sika deer (*Cervus nippon*). *Journal of Reproduction and Development* 48: 613–617.
- Klonisch, T., Schön, J., Sabine Hombach-Klonisch, S. and Blottner, S. 2006. The roe deer as a model for studying seasonal regulation of testis function. *International Journal of Andrology* 29: 122–128.
- Komatsu, T., Yamamoto, Y., Tsubota, T., Atoji, Y. and Suzuki, Y. 1996. Spermatogenic cycle in the testis of the Japanese black bear (*Selenarctos thibetanus japonicus*). *Journal of Veterinary Medical Science* 58: 329–335.
- Leblond, C. P. and Clermont, Y. 1952. Definition of the stages of the cycle of the seminiferous epithelium in the rat. *Annals of the New York Academy of Sciences* 55: 548–573.
- Leite, F. L., de Paula, T. A., da Matta, S. L., Fonseca, C. C., das Neves, M. T. and de Barros, J. B. 2006. Cycle and duration of the seminiferous epithelium in puma (*Puma concolor*). *Animal Reproduction Science* 91: 307–316.
- Li, L. H., Donald, J. M. and Golub, M. S. 2005. Review on testicular development, structure, function, and regulation in common marmoset. *Birth Defects Research. Part B, Developmental and Reproductive Toxicology* 74: 450–469.
- Maeda, S., Endo, H., Kimura, J., Rerkamnuaychoke, W., Chungsamarnyart, N., Yamada, J., Kurohmaru, M., Hayashi, Y. and Nishida, T. 1996. Classification of the cycle of the seminiferous epithelium in the common tree shrew (*Tupaia glis*). *Journal of Veterinary Medical Science* 58: 481–484.
- Millar, M. R., Sharpe, R. M., Weinbauer, G. F., Fraser, H. M. and

- Saunders, P. T. 2000. Marmoset spermatogenesis: organizational similarities to the human. *International Journal of Andrology* 23: 266–277.
- Mizukami, T., Kuwahara, S., Ohmura, M., Iinuma, Y., Izumikubo, J., Hagiwara, M., Kurohmaru, M., Hayashi, Y. and Nishida, T. 2001. The cycle of the seminiferous epithelium in the greater Japanese shrew mole, *Urotrichus talpoides*. *Journal of Veterinary Medical Science* 63: 31–35.
- Neves, E. S., Chiarini-Garcia, H. and França, L. R. 2002. Comparative testis morphometry and seminiferous epithelium cycle length in donkeys and mules. *Biology of Reproduction* 67: 247–255.
- Noller, D. W., Flickinger, C. J. and Howards, S. S. 1977. Duration of the cycle of the seminiferous epithelium in the guinea pig determined by tritiated thymidine autoradiography. *Biology of Reproduction* 17: 532–534.
- Oakberg, E. F. 1956. A description of spermiogenesis in the mouse and its use in analysis of the cycle of the seminiferous epithelium and germ cell renewal. *The American Journal of Anatomy* 99: 391–413.
- Ohtaishi, N. 1980. Determination of sex, age and death-season of recovered remains of Sika deer (*Cervus nippon*) by jaw and tooth-cement. *Kokogaku to Shizenkagaku (Archeology and Natural Science)* 13: 51–74 (in Japanese with English summary).
- Paula, T. A., Chiarini-Garcia, H. and França, L. R. 1999. Seminiferous epithelium cycle and its duration in capybaras (*Hydrochoerus hydrochaeris*). *Tissue and Cell* 31: 327–334.
- Pawar, H. S. and Wrobel, K.-H. 1991. Quantitative aspects of water buffalo (*Bubalus bubalis*) spermatogenesis. *Archives of Histology and Cytology* 54: 491–509.
- Schön, J., Göritz, F., Streich, J. and Blottner, S. 2004. Histological organization of roe deer testis throughout the seasonal cycle: variable and constant components of tubular and interstitial compartment. *Anatomy and Embryology* 208: 151–159.
- Segatelli, T. M., França, L. R., Pinheiro, P. F., Alemlida, C. C., Martinez, M. and Martinez, F. E. 2004. Spermatogenic cycle length and spermatogenic efficiency in the gerbil (*Meriones unguiculatus*). *Journal of Andrology* 25: 872–880.
- Suzuki, M., Kaji, K. and Nigi, H. 1992. Annual changes of testis size, seminiferous tubules and plasma testosterone concentration of wild Sika deer (*Cervus nippon yezoensis* Heude, 1884) in Hokkaido. *Journal of Veterinary Medical Science* 54: 551–556.
- Swierstra, E. E. 1968. Cytology and duration of the cycle of the seminiferous epithelium of the boar; duration of spermatozoan transit through the epididymis. *The Anatomical Record* 161: 171–186.
- Swierstra E. E., Gebauer M. R. and Pickett B. W. 1974. Reproductive physiology of the stallion. I. Spermatogenesis and testis composition. *Journal of Reproduction and Fertility* 40: 113–123.
- Tait, A. J. and Johnson, E. 1982. Spermatogenesis in the grey squirrel (*Sciurus carolinensis*) and changes during sexual regression. *Journal of Reproduction and Fertility* 65: 53–58.
- Toppari, J., Vihko, K. K., Räsänen, K. G., Eerola, E. and Parvinen, M. 1986. Regulation of stages VI and VIII of the rat seminiferous epithelial cycle *in vitro*. *Journal of Endocrinology* 108: 417–422.
- van Haaster, L. H. and de Rooij, D. G. 1993. Cycle of the seminiferous epithelium in the Djungarian hamster (*Phodopus sungorus sungorus*). *Biology of Reproduction* 48: 515–521.
- Wrobel, K.-H. and Schimmel, M. 1989. Morphology of the bovine Sertoli cell during the spermatogenic cycle. *Cell and Tissue Research* 257: 93–103.
- Wrobel, K.-H., Keßler, M. and Schimmel, M. 1993. Quantitative evaluations of the tubular epithelium in the testis of the Fallow deer (*Dama dama*). *Reproduction in Domestic Animals* 28: 1–13.
- Wrobel, K.-H., Reichold, J. and Schimmel, M. 1995. Quantitative morphology of the ovine seminiferous epithelium. *Annals of Anatomy* 177: 19–32.
- Yamauchi, K., Hamasaki, S., Takeuchi, Y. and Mori, Y. 1997. Assessment of reproductive status of sika deer by fecal steroid analysis. *Journal of Reproduction and Development* 43: 221–226.
- Yamauchi, S., Murai, T., Tanaka, H., Yamamoto, T. and Nishitani, Y. 1982. Study of male reproductive organs in Japanese deer, *Cervus nippon* (Nara Park)—Postnatal development and seasonal changes of testis and epididymis—. *The Japanese Journal of Animal Reproduction* 28: 81–88 (in Japanese with English summary).
- Zhu, L. J., Zong, S. D., Phillips, D. M., Moo-Young, A. J. and Bardin, C. W. 1997. Changes in the distribution of intermediate filaments in rat Sertoli cells during the seminiferous epithelium cycle and postnatal development. *The Anatomical Record* 248: 391–405.
- Zhou, Q., Nie, R., Prins, G. S., Saunders, P. T., Katzenellenbogen, B. S. and Hess R. A. 2002. Localization of androgen and estrogen receptors in adult male mouse reproductive tract. *Journal of Andrology* 23: 870–881.

Received 20 May 2008. Accepted 25 August 2008.