



# Follicular Loss of the Cryopreserved Canine Ovary after Xenotransplantation

その他（別言語等）のタイトル	凍結融解イヌ卵巣の異種移植後の卵胞減少について
著者（英）	Ishijima Takako, Abe Yasuyuki, Suzuki Hiroshi
journal or publication title	Journal of Mammalian Ova Research
volume	26
number	1
page range	61-65
year	2009
URL	<a href="http://id.nii.ac.jp/1588/00000620/">http://id.nii.ac.jp/1588/00000620/</a>

doi: info:doi/10.1274/jmor.26.61

—Brief Note—

## Follicular Loss of the Cryopreserved Canine Ovary after Xenotransplantation

Takako Ishijima<sup>1</sup>, Yasuyuki Abe<sup>1</sup> and Hiroshi Suzuki<sup>1\*</sup>

<sup>1</sup>Research Unit for Functional Genomics, National Research Center for Protozoan Diseases, Obihiro University of Agriculture and Veterinary Medicine, Inada, Obihiro 080-8555, Japan

**Abstract:** The effect of cryopreservation and subsequent xenotransplantation on the follicular reserve of the canine ovary by using non obese diabetic-severe combined immunodeficient (NOD-SCID) mice was examined. Vitrified-warmed canine ovarian tissues were placed into the ovarian bursa of mice, and then were removed and subjected to histological examination at 4 weeks after the transplantation. Over 30% of primordial follicles and 65% of early primary follicles survived after cryopreservation. However, regardless of breed or age, percentages of survived primordial follicles and early primary follicles after the transplantation ranged from 0–7% and from 0–15%, respectively. These results indicate that the majority of primordial follicles and early primary follicles in vitrified-warmed canine ovarian tissues disappear after xenotransplantation. Further studies will be required to be able to enhance the survival of transplanted cryopreserved ovarian follicles in canine.

**Key words:** Canine, Cryopreservation, Ovary, Transplantation

### Introduction

Advances in the diagnosis and treatment of cancer have resulted in a growing population of adolescent and adult long-term survivors of malignancies [1] with infertility problems due to induced premature ovarian failure [2]. Although several options are currently available to preserve fertility in cancer patients, cryopreservation of ovarian tissue is the only option available for prepubertal girls and women in need of immediate chemotherapy [3–8]. On the other hand, the cryopreservation of ovarian tissues is a potentially

significant technology for the preservation of the genetic resources of working dogs as well as other target animals [9]. However, it has been reported that a large proportion of follicles are lost during the initial ischemia which occurs after transplantation of mouse [10, 11], sheep [12, 13] and human ovaries [14, 15]. Thus, to corroborate the evidence for possible follicular loss after transplantation in canine ovarian tissues, we examined the effect of cryopreservation and subsequent xenotransplantation on the follicular reserve of the canine ovary by using non obese diabetic-severe combined immunodeficient (NOD-SCID) mice.

### Materials and Methods

Female NOD-SCID mice were purchased from a commercial supplier (Charles River Japan, Kanagawa, Japan). All animals were housed in polycarbonate cages, and maintained in a specific pathogen-free environment in light-controlled (lights-on from 07:00 to 19:00) and air-conditioned rooms (temperature: 24 ± 1°C, humidity: 50 ± 10%). They had access to standard laboratory chow (CE-2; CLEA Japan, Tokyo, Japan) and water *ad libitum*. The ovaries from 5-month-old and 6 month-old mixed breeds, a 4-month-old miniature dachshund and a 11-month-old toy poodle were frozen-thawed and transplanted into the ovarian bursa of 8-wk-old NOD-SCID mice. The cryopreservation procedures and ovarian transplantation were performed according to the method of Ishijima *et al.* [9]. Briefly, ovarian tissue was minced into 1.0–1.5 mm cubes, which were immersed in 1 M dimethyl sulfoxide (DMSO) at room temperature for 60 sec and then placed in a 1-ml cryotube (Nalge Nunc International KK, Tokyo, Japan) containing 5 µl of DMSO, and the tube was cooled on ice for 5 min. After addition of DAP 213 (2 M DMSO, 1 M acetamide, 3 M propylene glycol) solution [16] precooled on ice, the tube was cooled on ice for 5 min

Received: September 10, 2008

Accepted: December 2, 2008

\*To whom correspondence should be addressed.

e-mail: hisuzuki@obihiro.ac.jp

then immersed in liquid nitrogen. The grafts were stored in the liquid nitrogen for 2–6 months. For warming, the tube was removed from the liquid nitrogen, the liquid nitrogen in the tube was discarded and then the tube was allowed to stand at room temperature for 60 sec. After the addition of 900  $\mu$ l of 0.25 M sucrose prewarmed to 37°C into the tube, the suspension was quickly stirred by mild pipetting and washed with PBI [17] five times. A portion of the excised ovaries was fixed with 10% formalin to prepare pre-transplant ovarian tissue samples.

NOD-SCID mice ( $n = 13$ ) were anesthetized by intraperitoneal administration of sodium pentobarbital (5 mg/ml, Nembutal, Dainippon Pharmaceutical Co., Ltd., Osaka, Japan), then the dorsal skin was incised to draw out the ovaries. An incision was made in the lateral side of each ovary to remove the mouse ovary in the ovarian bursa, leaving a part to ensure blood flow to the canine ovarian xenograft after transplantation, and a piece of frozen-thawed canine ovarian tissue was introduced into the ovarian bursa. A hemostatic gelatin sponge (Spongel, S022Y01, Astellas, Japan) was also placed in the ovarian bursa. The skin incision was closed with a clip (9-mm auto clip, 427631, Becton Dickinson). The operated mice were placed on a warm plate until sufficient recovery had occurred to allow movement. At 4 weeks after the operation, the transplanted ovaries were removed and fixed with 10% formalin and subjected to hematoxylin and eosin staining together with the pre-transplant ovarian tissue samples. To evaluate the effects of freezing and thawing, and subsequent xenotransplantation, follicles that visibly contained an ovum (oocyte) with a nucleus were counted according to the classification of Oktay *et al.* [18] as follows. Primordial follicles comprise follicles containing an oocyte partially or completely encapsulated by squamous pregranulosa cells; Early primary follicles are follicles in which at least one of the pregranulosa cells had become columnar (enlarged); Primary follicles are follicles in which all of the granulosa cells exhibit enlargement and a single layer of granulosa cells; Transitional follicles comprise follicles containing an oocyte encapsulated by a 1–2 layer of columnar granulosa cells; Preantral follicles are made up of follicles containing an oocyte encapsulated by more than 2 layers of granulosa cells with no antrum formation; Antral follicles are follicles containing an oocyte encapsulated by more than 2 layers of granulosa cells with antrum formation. For pre-transplant ovarian tissues, ten tissue samples were randomly selected and the number of follicles in the ten tissue samples was

counted. The number of follicles in a circle of 900  $\mu$ m in diameter, i. e., a view field of 0.64 mm<sup>2</sup>, containing the highest number of follicles in each selected tissue sample was counted (for a total 10 view fields). This number was recorded as the number of follicles before transplantation. For transplanted ovarian tissue, five sections (7  $\mu$ m in thickness) were sequentially prepared for a tissue specimen (a block). A total of six graft samples were examined for each experimental group. The distance between sections was 40–50  $\mu$ m. The number of follicles in a circle of 900  $\mu$ m in diameter, i. e., a view field of 0.64 mm<sup>2</sup>, containing the highest number of follicles in each section, was counted (in a total of 5 fields of view). The survival rates of follicles were calculated as the number of follicles in pre-transplant ovarian tissues / number of follicles in fresh ovarian tissue samples  $\times$  100, and the number of follicles in transplanted ovarian tissues / number of follicles in pre-transplant ovarian tissue samples  $\times$  100.

The tissues and animals used in this study were treated under the Guiding Principles for the Care and Use of Research Animals established by Obihiro University of Agriculture and Veterinary Medicine.

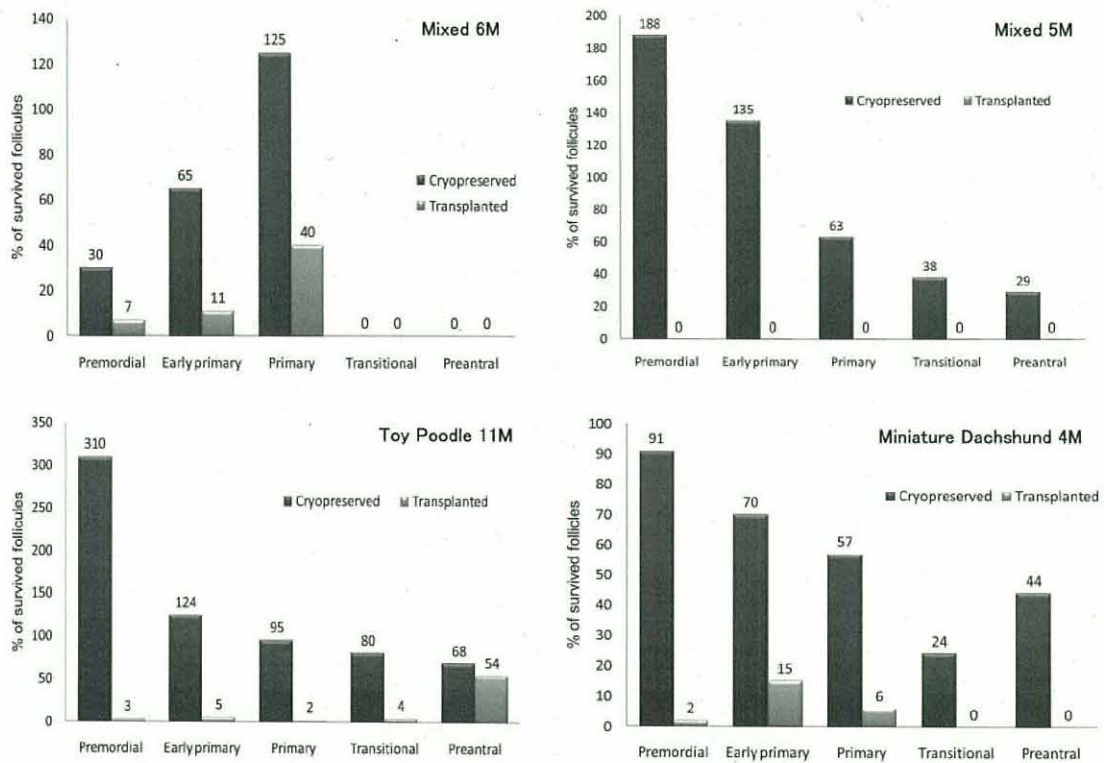
## Results

On autopsy, cryopreserved canine xenografts were distinguishable and were recovered in 13 of 13 mice (100%), and were identified in 20 of 26 (78%) of the transplanted sites. The average number of primordial, early primary, primary, transitional, preantral and antral follicles and the ratio of each developmental stage of follicles in fresh ovarian sections from the four bitches were varied. Namely, the mean numbers of primordial, early primary, primary, and transitional and preantral follicles per 0.64 square millimeter in the fresh ovary of the 6-month-old mixed breed were 38.4, 2.0, 0.2, and 0, respectively. While, for the 5-month-old mixed breed, the mean numbers of primordial, early primary, primary, transitional and preantral follicles per 0.64 square millimeter in fresh ovary of 6-month-old mixed breed were 8.2, 1.0, 2.4, 1.7 and 1.2 respectively. There were individual differences in the developmental stage of oocytes rather than the breed and/or age differences (Table 1). In addition, it seems that follicles are unevenly distributed in ovarian tissues, because the numbers of primordial and early primary follicles in the 5-month-old mixed breed and the 11-month-old toy poodle showed an increase in the number of follicles after cryopreservation. Namely, survival rates of primordial and early primary follicles after the

**Table 1.** Follicular loss of canine ovary after cryopreservation and subsequent xenotransplantation at 4 weeks after transplantation

Breed and age	Exp. Group	Mean number of follicles (/0.64 mm <sup>2</sup> )					
		Pri mordial	Early primary	Primary	Transitional	Pre antral	Antral
Mixed 6M	Fresh	38.4	2.0	0.2	0	0	0
	Cryo*	11.6	1.3	0.3	0	0.1	0
	Tp**	0.8	0.2	0.1	0.1	0.1	0.1
Mixed 5M	Fresh	8.2	1.0	2.4	1.7	1.2	0
	Cryo	15.5	1.4	1.5	0.7	0.4	0
	Tp	0	0	0	0	0	0
Toy Poodle 11M	Fresh	15.3	2.1	3.0	2.0	2.0	0.1
	Cryo	47.5	2.6	2.9	1.6	1.4	0
	Tp	1.5	0.1	0.1	0.1	0.7	0
Miniature Dachshund 4M	Fresh	14.8	3.3	4.1	3.6	0.8	0
	Cryo	13.4	2.3	2.4	0.9	0.4	0
	Tp	0.3	0.3	0.1	0	0	0

\*: Cryopreserved ovarian tissues. \*\*: Transplanted ovarian tissues.



**Fig. 1.** Percentages of surviving follicles in cryopreserved and subsequently transplanted canine ovaries. The survival rates of follicles were calculated as number of follicles in cryopreserved ovarian tissues / number of follicles in fresh ovarian tissue samples × 100, and number of follicles in transplanted ovarian tissues / number of follicles in cryopreserved ovarian tissue samples × 100.

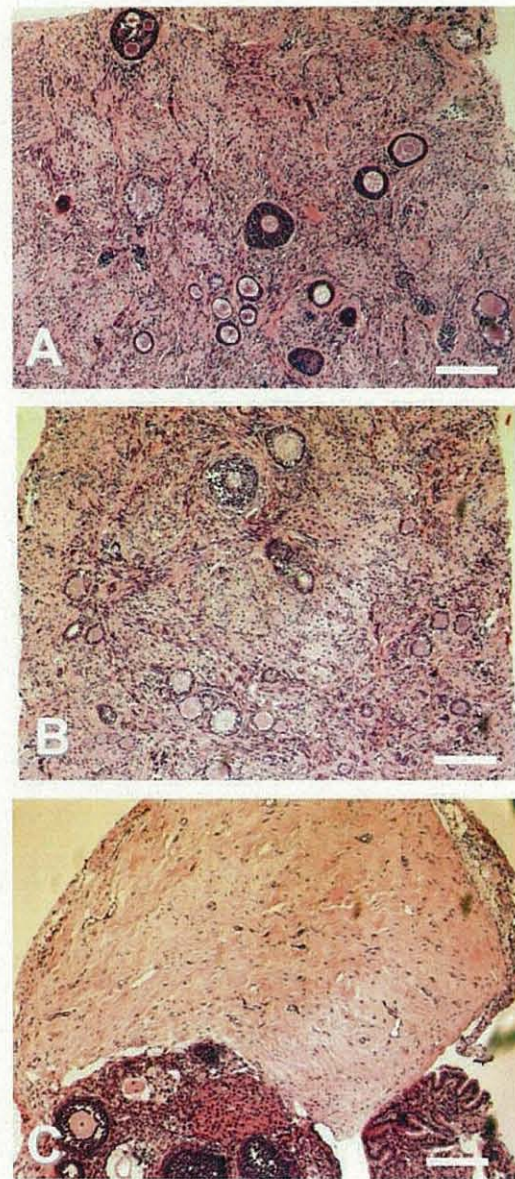
cryopreservation were 188% and 135% in the 5-month-old mixed breed, and 310% and 124% in the 11-month-old toy poodle, respectively (Fig. 1). However, as

shown in Fig. 1, the survival rates of primordial and early primary follicles after the cryopreservation in the 6-month-old mixed breed were 30% and 65%,

respectively. These results indicate that the follicular loss of the canine ovary was not drastically extended by the cryopreservation procedure itself. On the other hand, the detrimental effect of transplantation on the follicular survival was remarkable, even though the follicles were unevenly distributed in the ovarian tissues. The percentages of surviving primordial follicles and early primary follicles ranged from 0–7% and from 0–15%, respectively (Fig. 1).

### Discussion

Although the uneven distribution of follicles in the canine ovary make it difficult to interpret the results, it seems that a large proportion of follicles are lost after transplantation of ovaries in canine (Table 1 and Figs. 1 and 2) as well as other mammalian species [10–15, 19]. In fact, a high percentage of oocytes as well as granulosa cells survived the cryopreservation and thawing procedure [9, 20–22]. Previously we showed that there was no difference in the morphology and in the average number of primordial and primary follicles between the vitrified-warmed by DAP213 and fresh ovarian canine tissues [9]. It is believed that the reason the primordial follicle is observably resistant to cryoinjury is because the oocyte it contains has a relatively inactive metabolism, as well as the lack of a meiotic spindle, zona-pellucida and cortical granules [2]. Although it has been shown that proliferating cell nuclear antigen was detectable in many of the granulosa cells in the primary follicles of the grafts when canine ovarian tissues were cryopreserved in DAP213 and transferred into the ovarian bursa of NOD-SCID mice [9], the majority of primordial follicles in vitrified-warmed canine ovarian tissues disappeared after transplantation (Table 1 and Fig. 1). The main reason for the follicular loss after cryopreservation and xenografting seems to be the ischemic effect which takes place after transplantation rather than cryopreservation *per se* [11, 23]. Several attempts have been made to prevent the follicular loss of cryopreserved ovarian tissues after transplantation. However, an effective solution has not been found to date. Kim *et al.* [24] showed that a water soluble antioxidant (ascorbic acid) reduces apoptosis in the ovarian cortex by up to 24 h *in vitro*. It has been reported that treatment with vitamin E, a lipid soluble antioxidant, improved the survival of follicles in ovarian grafts by reducing ischemic injury [25]. Further studies will be required to be able to enhance the survival of transplanted cryopreserved ovarian follicles in canine as well as other mammalian species.



**Fig. 2.** Hematoxylin and eosin staining of ovarian tissues from a 5-month-old mixed breed. Canine ovaries were cryopreserved by vitrification. The fresh (A) and cryopreserved ovarian tissues (B) are morphologically equivalent. Panel C shows an ovarian tissue recovered from NOD-SCID mice 4 weeks after transplantation of the vitrified-warmed canine ovarian tissues into the bursa. Note the much deeper stain seen in the mouse ovarian tissue (lower) compared to the canine ovary (upper). Canine ovarian grafts (pale stain) successfully adhered to the mouse ovary. Many follicles are seen in canine fresh (A) and cryopreserved (B) ovarian tissues but not in transplanted tissue (C). White bar = 100  $\mu$ m.

### Acknowledgements

This study was supported by funds from the Ministry of Health, Labour and Welfare of Japan.

### References

- 1) Blatt, J. (1999): Pregnancy outcome in long-term survivors of childhood cancer. *Med. Pediatr. Oncol.*, 33, 29-33.
- 2) Donnez, J., Matinez-Madrid, B., Jadoul, P., Van Langendonck, A., Demylle, D. and Dolmans, M.M. (2006): Ovarian tissue cryopreservation and transplantation: a review. *Hum. Reprod. Update*, 12, 519-535.
- 3) Gosden, R.G., Baird, D.T., Wade, J.C. and Webb, R. (1994): Restoration of fertility to oophorectomized sheep by ovarian autografts stored at -196°C. *Hum. Reprod.*, 9, 597-603.
- 4) Donnez, J. and Bassil, S. (1998): Indications for cryopreservation of ovarian tissue. *Hum. Reprod. Update*, 4, 248-259.
- 5) Meirou, D., Ben Yehuda, D., Prus, D., Poliak, A., Schenker, J.G., Rachmilewitz, E.A. and Lewin, A. (1998): Ovarian tissue banking in patients with Hodgkin's disease: is safe? *Fertil. Steril.*, 69, 996-998.
- 6) Oktay, K., Newton, H., Aubard, Y., Salha, O. and Gosden, R.G. (1998): Cryopreservation of immature human oocytes and ovarian tissue: an emerging technology? *Fertil. Steril.*, 69, 1-7.
- 7) Donnez, J., Godin, P.A., Qu, J. and Nisolle, M. (2000): Gonadal cryopreservation in young patient with gynaecological malignancy. *Curr. Opin. Obstet. Gynecol.*, 12, 1-9.
- 8) Donnez, J., Dolmans, M.M., Matinez-Madrid, B., Demylle, D. and Van Langendonck, A. (2005): The role of cryopreservation for women prior to treatment of malignancy. *Curr. Opin. Obstet. Gynecol.*, 17, 333-338.
- 9) Ishijima, T., Kobayashi, Y., Lee, D.S., Ueta, Y.Y., Matsui, M., Lee, J.Y., Suwa, Y., Miyahara, K. and Suzuki, H. (2006): Cryopreservation of canine ovaries by vitrification. *J. Reprod. Dev.*, 52, 293-299.
- 10) Candy, C.J., Wood, M.J. and Whittingham, D.G. (1997): Effect of cryoprotectants on the survival of follicles in frozen mouse ovaries. *J. Reprod. Fertil.*, 110, 11-19.
- 11) Liu, J., Van der Elst, J., Van den Broecke, R. and Dhont, M. (2002): Early massive follicle loss and apoptosis in heterotopically grafted newborn mouse ovaries. *Hum. Reprod.*, 17, 605-611.
- 12) Aubard, Y., Piver, P., Cognie, Y., Fermeaux, V., Poulin, N. and Driancourt, M.A. (1999): Orthotopic and heterotopic autografts of frozen-thawed ovarian cortex in sheep. *Hum. Reprod.*, 14, 2149-2154.
- 13) Baird, D.T., Webb, R., Campbell, B.K., Harkness, L.M. and Gosden, R.G. (1999): Long-term ovarian function in sheep after ovariectomy and transplantation of autografts stored at -196°C. *Endocrinology*, 140, 462-471.
- 14) Newton, H., Aubard, Y., Rutherford, A., Sharma, V. and Gosden, R.G. (1996): Low temperature storage and grafting of human ovarian tissue. *Hum. Reprod.*, 11, 1487-1491.
- 15) Oktay, K., Newton, H. and Gosden, R.G. (2000): Transplantation of cryopreserved human ovarian tissue results in follicle growth initiation in SCID mice. *Fertil. Steril.*, 73, 599-603.
- 16) Nakagata, N. (1993): Survival of mouse morulae and blastocysts derived from in vitro fertilization after ultra rapid freezing. *Jikken Dobutsu*, 42, 229-231.
- 17) Whittingham, D.G. (1974): Embryo banks in the future of developmental genetics. *Genetics*, 78, 395-402.
- 18) Oktay, K., Schenken, R.S. and Nelson, J.F. (1995): Proliferating cell nuclear antigen marks the initiation of follicular growth in the rat. *Biol. Reprod.*, 53, 295-301.
- 19) Nisolle, M., Godin, P.A., Casanas-Roux, F., Qu, J., Motta, P. and Donnez, J. (2000): Histological and ultrastructural evaluation of fresh and frozen-thawed human ovarian xenografts in nude mice. *Fertil. Steril.*, 74, 122-129.
- 20) Seibzehrubl, E., Kohl, J., Dittrich, R. and Wildt, L. (2000): Freezing of human ovarian tissue-not the oocytes but the granulosa is the problem. *Mol. Cell Endocrin.*, 169, 109-111.
- 21) Martinez-Madrid, B., Dolmans, M. M., Van Langendonck, A., Defrere, S. and Donnez, J. (2004): Freezing-thawing intact human ovary with its vascular pedicle with a passive cooling device. *Fertil. Steril.*, 82, 1390-1394.
- 22) Maltaris, T., Beckmann, M.W., Binder, H., Mueller, A., Hoffmann, I., Koelbl, H. and Dittrich, R. (2007): The effect of a GnRH agonist on cryopreserved human ovarian graft in severe combined immunodeficient mice. *Reproduction*, 133, 503-509.
- 23) Maltaris, T., Dimmler, A., Muller, A., Binder, H., Hoffmann, I., Kohl, I., Siebzehrubl, E., Beckmann, M.W. and Dittrich, R. (2005): The use of an open-freezing system with self-seeding for cryopreservation of mouse ovarian tissue. *Reprod. Dom. Anim.*, 40, 250-254.
- 24) Kim, S.S., Yang, H.W., Kang, H.G., Lee, H.H., Lee, H.C., Ko, D.S. and Gosden, R.G. (2004): Quantitative assessment of ischemic tissue damage in ovarian cortical tissue with or without antioxidant (ascorbic acid) treatment. *Fertil. Steril.*, 82, 679-685.
- 25) Nugent, D., Newton, H., Gallivan, L. and Gosden, R. G. (1998): Protective effect of vitamin E on ischemia-reperfusion injury in ovarian grafts. *J. Reprod. Fertil.*, 114, 341-346.