

A Case of Equine Motor Neuron Disease (EMND)

Naoki SASAKI¹⁾, Michiaki YAMADA¹⁾, Yoshinori MORITA²⁾, Hidefumi FURUOKA³⁾, Miyuki ITOH³⁾, Motoyoshi SATOH¹⁾ and Haruo YAMADA¹⁾

¹⁾Departments of Clinical Veterinary Science and ³⁾Pathological Science, Obihiro University of Agriculture and Veterinary Medicine, Inada, Obihiro, Hokkaido 080-8555 and ²⁾Draft horse Clinic, Asahikawa-city, Hokkaido, Japan

(Received 9 June 2006/Accepted 18 August 2006)

ABSTRACT. We report a case of EMND in a heavy horse that was bred and trained in Hokkaido, Japan. Clinical symptoms included severe ataxia of all four limbs, tilted head, lethargy, and flaccid lips. Numerous axonal degenerations and swellings were observed in nuclei, mostly in the cerebellar dentate nucleus and the nucleus of the hypoglossal nerve, and in the ventral horn of the spinal cord. In the ventral horn of the spinal cord, neuronal degeneration, swelling, and/or necrosis were observed sporadically. The case was diagnosed as EMND from the clinical symptoms and pathological findings.

KEY WORDS: ataxia, EMND, equine.

J. Vet. Med. Sci. 68(12): 1367–1369, 2006

Equine motor neuron disease (EMND) is an acquired motor neuron disease of horses, which was first reported in 1990 from the northeast of the United States [2]. More than 100 cases have been reported worldwide since then, including cases in Canada, United Kingdom, Switzerland, Belgium, and Brazil. In Japan, EMND cases were reported in 1994 [4] and 1998 for an Anglo-Arab horse (aged 9 years, Okayama-ken) and an Arab horse (aged 14 years, Hokkaido) [3]. The number of reported EMND cases has increased outside of Japan. This is thought to stem from EMND having been mistakenly diagnosed as a different disease in historical practice [2, 7], and thus, the number of reported incidences is expected to increase in Japan as well.

In EMND, the brainstem, cerebellum, and/or ventral horn of the spinal cord are degenerated and/or necrosed due to selective damage of motor neurons, and neurogenic atrophy is observed in skeletal muscles, which are controlled by motor neurons [5, 9]. Accordingly, symptoms include tremors, weight loss, spasms, gait with short steps, wasting, stress on the hind limbs, flat head, and tail raising [2].

This is a report of an EMND case of a heavy horse, bred and trained in the Tokachi area of Hokkaido, Japan. In February 2005, the horse (male, aged 5 years, 980 kg body weight) first visited the Hospital at Obihiro University of Agriculture and Veterinary Medicine. It was referred to our institution after being affected with a severe gait abnormality, and we found severe ataxia of the fore and hind limbs 2 days ago. The horse collided with the wall and door as it came out of the barn and leaned against the wall. Symptoms included lethargy, torticollis, and flaccid lower lip (Fig. 1). Gait examination, palpation, laboratory tests, and myelogram were performed. Despite intravenous steroid therapy with 400 mg dexamethasone, symptoms did not improve. The horse was given a poor prognosis, and a pathologic autopsy was performed.

Gross examination: Severe ataxia of all four limbs was observed, but other abnormalities, including tenderness to palpitation of the lumbar and lower limbs, were not noted.

Results from peripheral blood tests: As shown in Table 1, red blood cell (RBC) count, white blood cell (WBC) count, and hematocrit (Hct) were within normal ranges. Results of blood electrolyte, blood cell fraction, and blood chemistry tests were within normal ranges. Further, serum vitamin E was within the normal range (Table 2).

Results from myelogram: A contrast medium (Omnipack, 50 mL) was administered between the first and second cervical vertebrae using a spinal needle, and images were taken by a portable x-ray unit. Abnormal findings characteristics of Wobbler syndrome, such as projection of vertebral bodies and deformation of articular processes, were not found.

Results from necropsy and histopathological tests: No significant findings were noted externally, including with respect to nerve tissues. Following necropsy, nerve tissues, including the cerebrum, cerebellum, medulla oblongata, the first to seventh cervical vertebrae, and spinal cord, were dyed with hematoxylin and eosin (HE) and Bielschowsky stains for microscopic observation. Numerous axonal swellings and degenerations were found in various nuclei, such as the cerebellar dentate nucleus, the nucleus of the hypoglossal nerve, and the trigeminal nucleus (Fig. 2).



Fig. 1. The horse at rest in the barn—Its head appears to be resting against the wall. The lower lip is flaccid.

Table 1. Results from peripheral blood tests

| Variable | Value | Variable | Value | Variable | Value |
|----------|--------------------------------|----------|--------------------------------|----------|-------|
| RBC | $1065 \times 10^4/\mu\text{l}$ | Na | 138 mEq/l | LY | 41% |
| WBC | $95 \times 10^2/\mu\text{l}$ | K | 4 mEq/l | ST | 8% |
| MCV | 41 fl | Cl | 89 mEq/l | SE | 40% |
| MCH | 13.5 pg | Hct | 43% | EO | 8% |
| MCHC | 33.1 g/dl | PLT | $21.8 \times 10^4/\mu\text{l}$ | MO | 3% |

Table 2. Results from blood chemistry tests

| Variable | Value | Variable | Value | Variable | Value |
|---------------|------------|----------|------------------------|----------|------------------------|
| TP | 6.06 g/dl | D-BIL | 13.7 $\mu\text{mol/l}$ | Glu | 55 mg/dl |
| AST | 301 u/l | T-CHO | 83 mg/dl | IP | 2.6 mg/dl |
| γ -GTP | 26 u/l | Ca | 9.5 mg/dl | | |
| TG | 15 mg/dl | V_E | 0.32 mg/dl | NEFA | 520 mmol/l |
| BUN | 11.3 mg/dl | Mg | 1.49 mg/dl | T-BIL | 13.7 $\mu\text{mol/l}$ |

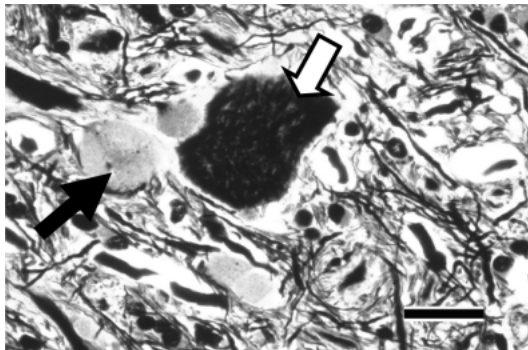


Fig. 2. Cerebellum (histological examination, Bielschowsky stain, $\times 400$, Bar: 50 μm)—Black arrow indicates an axonal degeneration; white arrow indicates a nerve cell body. Axonal degenerations in the cerebellum were argentaffin.

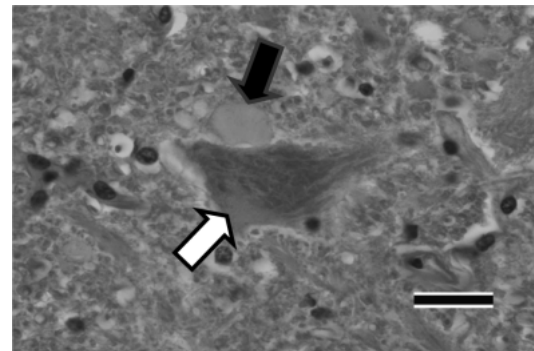


Fig. 3. Spinal cord (histological examination, HE-stained axonal swelling and degeneration, $\times 400$, Bar: 50 μm)—Black arrow indicates an axonal degeneration; white arrow indicates a nerve cell body. Axonal swellings and degenerations similar to that in the cerebellum were found in the ventral horn of the spinal cord.

Axonal degenerations were located around or adjacent to nerve cell bodies, appeared as large acidophilic spherules, and were argentaffin. In the spinal cord, axonal swellings and degenerations similar to that of the cerebellum were found in the ventral horn (Fig. 3). Nerve cell bodies were acidophilic, and vacuole formations were observed around them (Fig. 4). Lesions were localized to the cerebellum and spinal cord, and numerous axonal swellings and degenerations were observed in nuclei, mainly the cerebellar dentate nucleus and the nucleus of the hypoglossal nerve, and the vertebral horn of the spinal cord. Further, neuronal degeneration, swelling, and/or necrosis were found sporadically. Some fibrosis was observed in peripheral nervous fibers. Indications of possible bacterial, viral, or protozoan infection were not found. Neurogenic atrophy seen in skeletal muscles was relatively mild.

This case was diagnosed as selective damage of motor neurons, EMND, based on the clinical symptoms and pathological findings. In typical EMND, neurons in the spinal cord and cerebellum are damaged, neurogenic atrophy develops in muscles, and damage to type I fibers is most

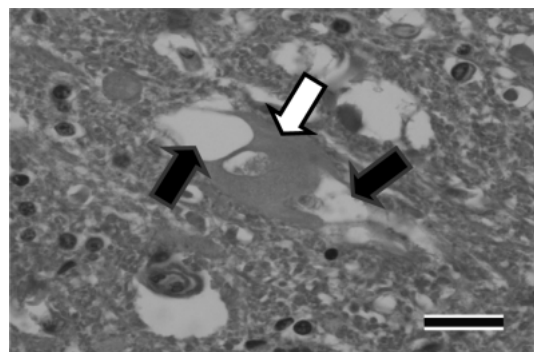


Fig. 4. Spinal cord (histological examination, HE-stained vacuolar degeneration, $\times 400$, Bar: 50 μm)—Black arrows indicate vacuolar degenerations; white arrow indicates a nerve cell body. Nerve cell bodies in the ventral horn of the spinal cord were acidophilic. Vacuoles were formed around nerve cell bodies.

extensive [8]. Thus, symptoms include tremors, weight loss, spasms, gait with short steps, wasting, stress on the hind limbs, flat head, and tail raising [2, 8]. Lethargy and torticollis were also observed in this case. Since these symptoms are usually associated with damage to the cerebellum, the cerebellar damage found by histopathology was thought to be the cause. Tremors are known to develop when more than 30% of muscle-controlling nerves are damaged [1]. This case did not develop tremors, possibly because EMND was in an early stage and muscle atrophy was not yet significant.

Typical EMND cases develop gait with short steps due to neurogenic atrophy of muscles. Severe ataxia was observed in our case although muscle atrophy was not significant. This may have been related to the cerebellar damage as well. The flaccid lip sign observed in this subject was similar to a reported EMND sign where horses rest their jaws on an object [2]. This sign was thought to be associated with degenerations of nerve fibers in nuclei of facial nerves or that of more peripheral areas.

Epidemiology suggests that EMND is more common in older horses (10–16 years), thoroughbred and quarter horses, and horses that are kept in a barn for a long period of time without being pastured [2, 7]. Possible causes of EMND include reduced serum vitamin E and depleted nutritional antioxidants, which lead to superoxide-related oxidation problems in neurons [1]. We may infer that depleted vitamin E in feed can cause reduced serum vitamin E and EMND development. However, EMND has also been reported in horses that have received adequate vitamin E [6]. Development of EMND requires long-term depletion of

antioxidants as well as chronic problems with neuronal oxidation. In our case, the vitamin E level was within a normal range, but problems with neuronal oxidation were thought to be advanced. As suggested by histological findings, we diagnosed this case as a relatively early stage of EMND.

Differential diagnosis is necessary for EMND, since symptoms of EMND are similar to that of Wobbler syndrome and other diseases that cause ataxia. Accordingly, further studies may be necessary to accurately diagnose EMND and understand its etiology.

REFERENCES

1. Diver, T. J., De Lahunta, A., Hintz, H. F., Riis, R. C., Jackson, C. A. and Mohammed, H. O. 2001. *Equine. Vet. J.* **13**: 63–67.
2. Divers, T. J., Mohammed, H. O., Cummings, J. F., Valentine, B. A., Lahunta, A. DE., Jackson, C. A. and Summers, B. A. 1994. *Equine. Vet. J.* **26**: 409–415.
3. Furuoka, H., Hasegawa, M., Kobayashi, Y. and Matsui, T. 1999. *J. Vet. Med. Sci.* **61**: 557–560.
4. Kuwamura, M., Iwaki, M., Yamate, J., Kotani, T., Sakuma, S. and Yamashita, A. 1994. *J. Vet. Med. Sci.* **56**: 195–197.
5. Ludolph, A. C. 1996. *Neurology.* **47**: 228–232.
6. McGorum, B. C., Mayhew, I. G., Deprez, P., Gikkies, K., Mair, T. S., Nollent, H., Wijnberg, I. D. and Hahn, C. N. 2006. *Equine. Vet. J.* **38**: 47–51.
7. Mohammed, H. O., Cummings, J. F., Divers, T. J., Rua-Domech, R de la. and de Lahnter, A. 1994. *Vet. Res.* **25**: 275–278.
8. Palencia, P. A., -Rothe, E., Jose, Q. A. and Rivero, L. L. 2005. *Acta. Neuropathol.* **109**: 272–284.
9. Valentine, B. A., DeLahunta, A., Geprge, C., Summers, B. A., Cummings, J. F., Divers, T. J. and Mohammed, H. O. 1994. *Vet. Pathol.* **31**: 130–138.